

## HISTOLOGICAL STUDY ON RETEST REACTION IN CONTACT SENSITIVITY TO DNCB

Shojiro NAKAGAWA, Masako GOTOH, Shinji FUKUSHIRO\*,  
Tadahiro AOSHIMA\*\* and Kihei TANIOKU

*Department of Dermatology, Kawasaki Medical School,  
Kurashiki, 701-01,*

*\*Department of Dermatology, Okayama University Medical School,  
Okayama, 700, and*

*\*\*Department of Dermatology, Kurashiki Central Hospital,  
Kurashiki, 710, Japan*

*Accepted for Publication on Dec. 12, 1977*

### Abstract

Chronologic development of histologic changes of the retest reaction was investigated in guinea pigs with contact sensitivity to DNCB. There was a striking influx of eosinophils into skin accompanied by varying stage of vacuole in epidermis, well correlated with the gross reaction, i.e. beginning at about three hours and maximal at about nine hours after antigenic challenge. The significance of these findings is discussed.

### INTRODUCTION

The term 'retest reaction' is used here to describe an accelerated reaction which appears at a previous positive skin test site after renewed local administration of antigen. The reaction in contact sensitivity was reported earlier<sup>1,2)</sup>, but the details were not clear. The previous work indicated that the retest reaction in guinea pigs with contact sensitivity to DNCB was characterized macroscopically by its accelerated time course vis-à-vis the usual contact reaction and microscopically by cutaneous eosinophilia<sup>3)</sup>. In the present paper, chronologic development of histologic changes of the retest reaction was described in detail.

### MATERIALS AND METHODS

*Animals:* Male Hartley strain guinea pigs, weighing 300 to 400 g, were used.

*Sensitization and testing:* Animals were sensitized by an application of 0.1 ml of 5 per cent solution of DNCB in ethanol to both sides of the

中川昌次郎, 後藤昌子, 福代新治, 青島忠恕, 谷奥喜平

inguinal skin. Skin reactions consisting of marked redness and slight swelling were elicited 7 days after sensitization with 0.01 ml of 0.2 per cent DNCB-ethanol solution, painted on the shaved flank skin. Seven days after the preparatory skin test, retesting by painting with DNCB was done at the site of prior reaction, the same antigen dose being used.

*Histological examination:* Sections from retest reaction and virgin reaction sites, stained with hematoxylin and eosin, were studied at various intervals after the eliciting dose of DNCB. A limited number of Giemsa-stained sections were also examined.

### RESULTS

*Gross description of the retest reaction:* In animals with contact sensitivity to DNCB tested with DNCB and subsequently retested at the same site, a retest reaction was observed. This lesion presented the same gross characteristics with usual contact reaction at a virgin site (not previously tested). It was a sharply defined redness with swelling, first visible three hours after patch testing and increasing rapidly to a maximum nine hours. At a new site in the same animal, inspection revealed the beginning of redness at three hours; the reaction increased slowly to reach maximal redness and swelling at 12 to 24 hours. Retest reactions were largely faded at 24 hours, the time at which reactions at new sites showed a maximum. Up to 24 hours, the reactions were more intense at the retest site than at the new site, as described in detail previously<sup>3</sup>.

*Histologic character of the retest reaction:* Before retesting, the skin which had been the site of a contact sensitivity reaction to DNCB 7 days previously showed marked thickening of the epidermis and slight mononuclear cell infiltration immediately under the epidermis. Three hours after retesting by painting with DNCB at the site of prior reaction, the capillaries of the upper and middle portions of the dermis were dilated and, interstitial edema was present. The cellular infiltration consisting of mononuclear and polymorphonuclear cells was perivascular and diffuse between the collagen fibrils in the upper dermis. A small number of polymorphonuclear and mononuclear cells had entered the epidermis (Fig. 1). Circumscribed, slight intercellular edema of the epidermis had developed.

In the six-hour lesions the infiltration of the upper dermis had increased and intense extravasation of the polymorphonuclear cells was

in progress. The epidermis had become slightly acanthotic and contained a number of regions invaded by groups of polymorphonuclear cells. The intercellular edema of epidermis had spread into a large regions of epidermis, accompanied by the early stage of vacuole. Some subcorneal micro-abscess containing polymorphonuclear cells were observed in the uppermost of hair follicles (Fig. 2). The varying epidermal changes observed in six-hour lesions reached a maximum in nine-hour lesions. All of the challenged epidermal surface was extensively invaded by polymorphonuclear cells, and accompanied by varying stage of vacuole formation (Fig. 3). In some instances distinction between epidermis and dermis was difficult due to disruption of the epidermal structure by intense vacuolization and formation of micro-abscess (Fig. 4). The cell infiltration had reached a maximum and was uniformly diffuse throughout the upper dermis. Eosinophils were generally the predominant cells in infiltrating polymorphonuclear cells.

The dermis showed only a moderate infiltration in twelve-hour lesions. Vasodilatation and interstitial edema in the dermis were ameliorated. The epidermal cells were necrotic in a wide area. The staining property of the epidermal layer was altered, for the affinity for eosin increased. There could be seen a loss of cellular integrity and disappearance of the demarcation between nucleoplasm and cytoplasm of epidermal cells. Fragments of infiltrating cells remained in such epidermis. Collagen fibrils immediately under the necrotic epidermis were also degenerative. In twenty-seven-hour lesions the dead epidermis and the fragments of the infiltrating cells were exfoliated, and a new epidermal layer covered the dermis. Acanthosis and slight infiltration of mononuclear cells could be observed in the upper dermis. In some regions spongiotic change of epidermis with mononuclear infiltrate was detectable.

#### DISCUSSION

In the present study, chronologic development of histologic changes of the retest reaction to DNCB was described in detail. The most striking feature in microscopic findings of the retest reaction was an influx of eosinophils into the skin, beginning at about three hours and maximal at about nine hours after retesting. In the usual contact reaction at the new site (not previously tested), eosinophil infiltration occurred to a very small extent. Epidermal changes were far more intense in retest reaction than in the usual contact reaction. The time course and intensity of eosinophil infiltration were well correlated with the time

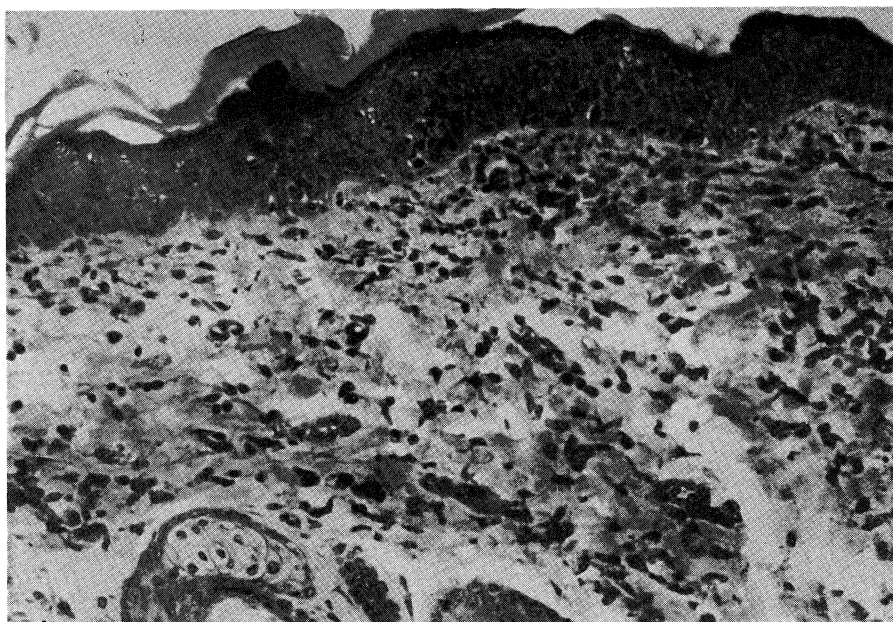


Fig. 1. Retest reaction at three hours; showing cellular infiltrate consisting of mononuclears and polymorphonuclears in either epidermis or dermis. Hematoxylin and eosin;  $\times 100$ .

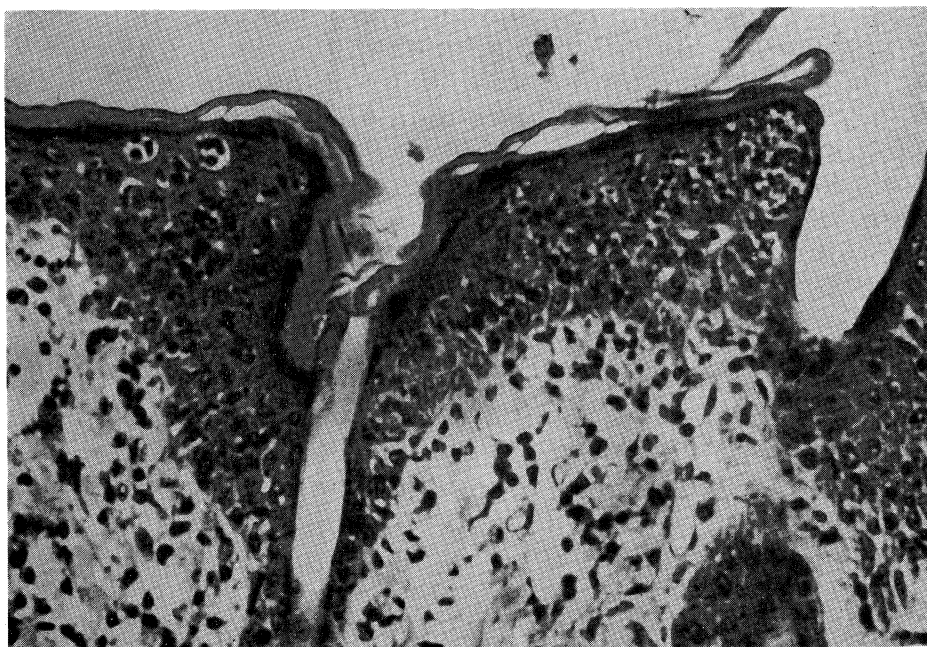


Fig. 2. Retest reaction at six hours; showing subcorneal micro-abscess containing polymorphonuclears in the uppermost of hair follicles. Hematoxylin and eosin;  $\times 200$ .

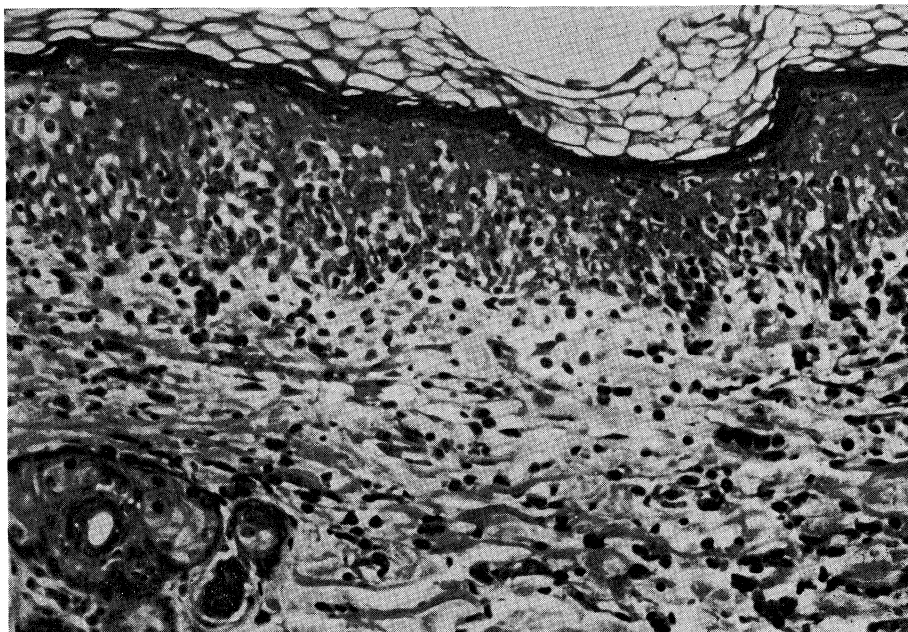


Fig. 3. Retest reaction at nine hours. Epidermis is invaded by polymorphonuclears, and accompanied varying stage of vacuole formation. Hematoxylin and eosin;  $\times 100$ .

course and intensity of gross reaction. Cutaneous eosinophilia of the retest reaction has been pointed out in animals and humans with contact sensitivity or delayed type hypersensitivity by several workers<sup>1,2,4</sup>. The function of the eosinophils is not clear at present time.

We do not at present know the mechanism of the retest reaction. Arnason and Waksman<sup>4</sup> have concluded that, despite unique feature of retest reaction, it is closely allied to delayed sensitivity. Polak *et al.*<sup>5</sup> have claimed that antigen sensitive cells previously involved in test reaction are still present in cell infiltration at the site of the old contact reaction. It has also been demonstrated in the previous works<sup>3,6</sup> that the antigen sensitive cells remaining at the old test site are, at least in part, specifically directed toward the conjugate of hapten with epidermal proteins. It is reasonable to assume that the antigen sensitive cells drawn to the reaction site by the preparatory contact reaction react with the conjugate of hapten with epidermal proteins formed at the time of retesting, and then elicit retest reaction.

#### Acknowledgment

This study was supported by a grant from the Japanese Ministry of Education (No. 257285).

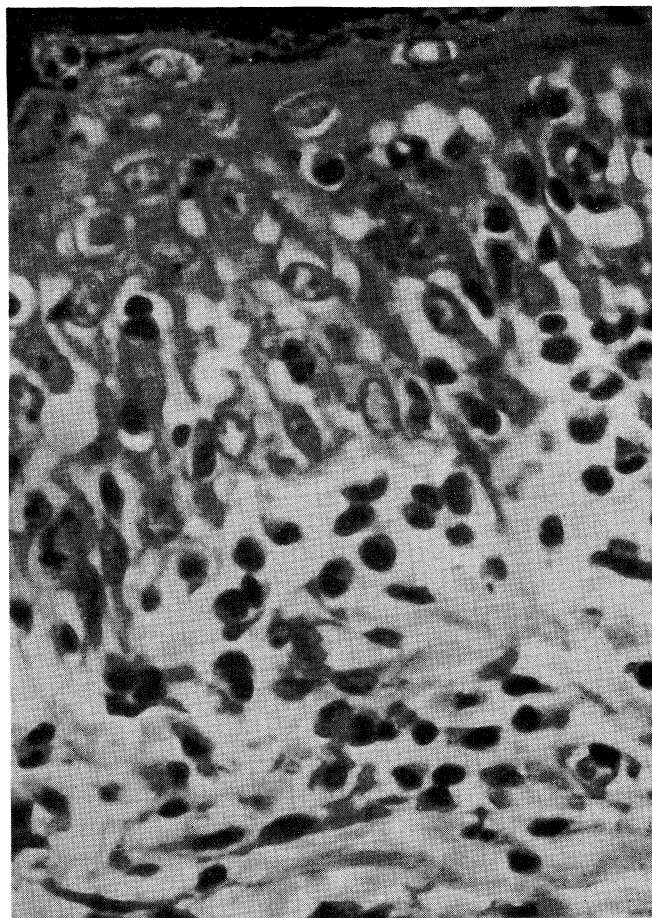


Fig. 4. High power view of Figure 3. Distinction between epidermis and dermis is difficult in disruption of epidermal structure by intense vacuolization. Predominant infiltrating cells are polymorphonuclears.  $\times 400$ .

#### REFERENCES

- 1) Bandmann, Von H. J.: Die Histologie doppelt Lappchenproben. *Dermatologica* 124: 205-217, 1961
- 2) Klaschka, F.: Tierexperimentelle Studien zum Kontaktekzem. V. Sensibilisierung und Desensibilisierung mit Epidermis-2,4-Dinitrochlorobenzol-Konjugaten. Versuch einer Gesamtchau des experimentellen DNCB-Ekzems. *Arch. klin. exp. Derm.* 233: 329-346, 1968
- 3) Nakagawa, S., Fukushima, S., Gotoh, M., Kohda, M., Namba, M. and Tanioku, K.: Studies on the retest reaction in contact sensitivity to DNCB. *Dermatologica* (in press)
- 4) Arnason, B. G. and Waksman, B. H.: The retest reaction in delayed sensitivity. *Lab. Invest.* 12: 737-747, 1963
- 5) Polak, L., Turk, J. L. and Frey, J. R.: Studies on contact hypersensitivity to chromium compounds. *Progr. Allergy* 17: 145-226, 1973
- 6) Fukushima, S., Nakagawa, S., Gotoh, M., Koshizawa, M. and Tanioku, K.: The distribution of antigen in flare up reaction in contact sensitivity to DNCB.: *Immunology* (in press)