

Intraosseous schwannoma of the mandible : A case report

Satoshi ITO¹⁾, Toshiko MANDAI¹⁾, Kosei ISHIDA¹⁾, Hiroyo DEGUCHI¹⁾
Tsuyoshi HATA¹⁾, Isao IREI²⁾, Masaru HOSODA¹⁾

1) Department of Oral Surgery, 2) Department of Pathology, Kawasaki Medical School, 577 Matsushima, Kurashiki, 701-0192, Japan

ABSTRACT A 70-year-old man was referred to our department with the chief complaint of pain and swelling in the right posterior mandible. Panoramic radiography disclosed a large, unilocular, radiolucent lesion with distinct borders involving the right mandibular body and ramus, extending from the second molar to the upper portion of the ramus. A complete excision was achieved by removing the tumor with the inferior alveolar nerve from the right mandible. Histologically, Antoni-A tissue was the predominant microscopic pattern, but it occasionally alternated with Antoni-B areas. Immunohistochemical staining for S-100 proteins showed diffusely positive findings. An examination confirmed a diagnosis of an intraosseous schwannoma of the mandible.

(Accepted on July 6, 2009)

Key words : schwannoma, mandible, inferior alveolar nerve

INTRODUCTION

Schwannoma is a benign tumor from Schwann cells of the neural sheath. Although the occurrence of schwannomas in the head and neck area is relatively high, an intraosseous schwannoma is rare, presenting in less than 1% of benign primary bone tumors¹⁾. We herein report a rare case of an intraosseous schwannoma of the mandible.

CASE REPORT

A 70-year-old man with pain and swelling in the right mandibular region was referred to our department from an outside dental clinic in December 2007. His dental history indicated that his right mandibular third molar had received root canal treatment for periodontitis three weeks prior

to the first dental examination. However, pain and swelling remained even after treatment. He had a medical history of hypertension.

A clinical examination revealed slight right submandibular swelling and buccal gingival swelling of the second and third molar region. A neurosensory examination was normal. Panoramic radiography revealed a large, unilocular, radiolucent lesion with distinct borders involving the right mandible, extending from the second molar to the upper portion of the ramus. There were no apparent signs of resorption or displacement of the roots of the right mandibular third molar (Fig. 1). CT images confirmed a well-defined osteolytic lesion of the cortex in the right posterior mandible (Fig. 2). We suggested that the cause of the pain and swelling

Corresponding author
Satoshi Ito
Department of Oral Surgery, Kawasaki Medical School,
577 Matsushima, Kurashiki, 701-0192, Japan

Phone : 81 86 462 1111
Fax : 81 86 462 1199
E-mail : hibitan@med.kawasaki-m.ac.jp

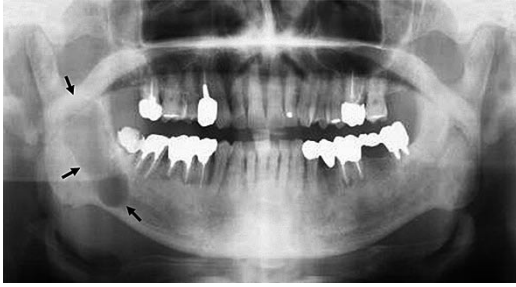


Fig. 1. Panoramic radiography showing a large, unilocular, radiolucent lesion with distinct borders involving the right mandible, extending from the second molar to the upper portion of the ramus (arrows).

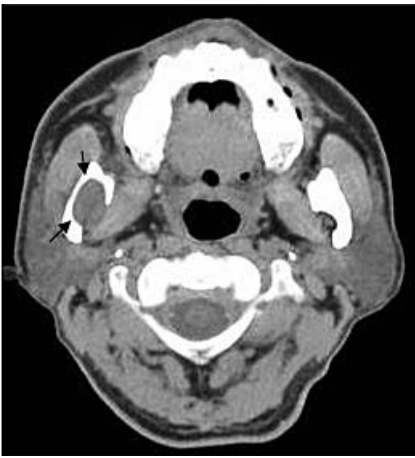


Fig. 2. An axial CT scan showing a space-occupying mass with clear borders. Compressive resorption of the mandible can be observed (arrows).

was pericoronitis of the right mandibular third molar, and the tumor was discovered by chance. The clinical diagnosis was a benign tumor of the right mandible.

With the patient under general anesthesia, the right mandibular third molar was extracted, a buccal mucoperiosteal flap was reflected, and a bony window was made to gain access to the tumor. The tumor was found to be encapsulated and it was easily separated from the bony wall. Since the right inferior alveolar neurovascular bundle passed through the lesion its preservation was impossible and an *en bloc* resection was thus performed (Fig. 3). Microscopically, the tissue revealed neoplastic connective tissue arranged in short fascicles,

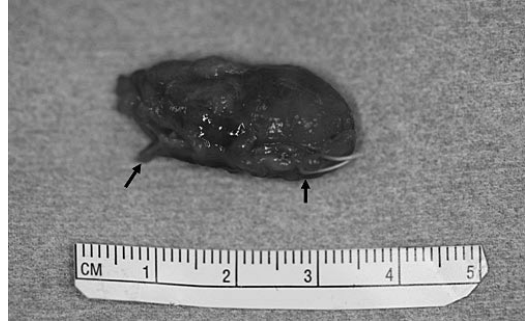


Fig. 3. A photograph of the resected well-encapsulated tumor with the inferior alveolar nerve (arrows).

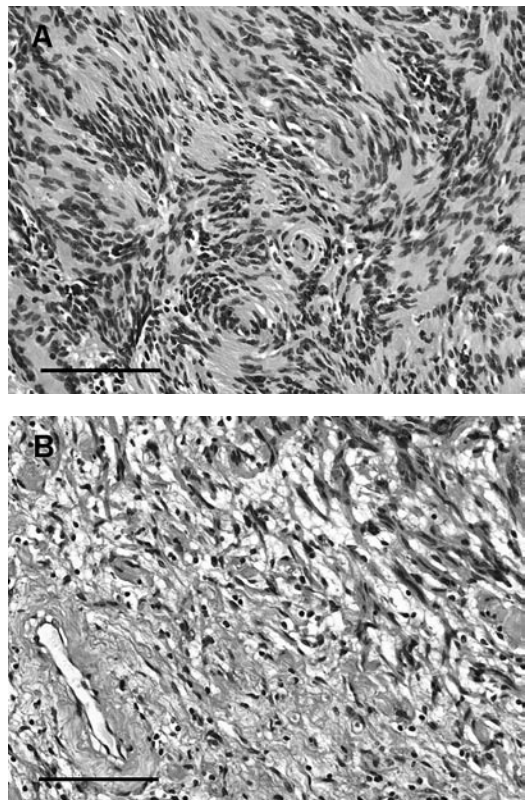


Fig. 4. (A) A photomicrograph of a resected specimen showing Antoni-A type tissue consisting of palisading arranged nuclei, and (B) an Antoni-A and B junctional region (hematoxylin and eosin stain). Scale bar = 100 μ m.

composed of cells with aligned long nuclei, similar to Schwann cells. Some of these nuclei formed typical palisades. Antoni-A tissue was the predominant microscopic pattern, but occasionally alternated with Antoni-B areas (Fig. 4A, B).

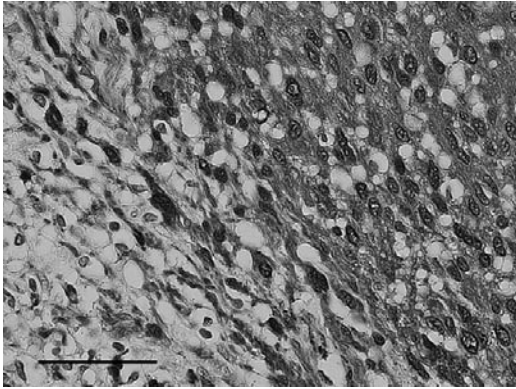


Fig. 5. A photomicrograph of a resected specimen showing positive immunostaining for S-100 protein. Scale bar = 50 μ m.

Immunohistochemical staining for S-100 proteins showed diffusely positive findings (Fig. 5). The diagnosis was an intraosseous schwannoma arising from the inferior alveolar nerve. Postoperative radiographic follow-up showed bone regeneration during the last 16 months.

DISCUSSION

Schwannoma (neurinoma, neurilemmoma) is a benign tumor arising from the peripheral neural sheath¹⁾. Although the head and neck region is one of the most common sites for benign nerve-sheath tumors, intraoral lesions are unusual, particularly in the intraosseous region of the jaw²⁾. In 39 cases of intraosseous schwannoma of the mandible reviewed by Chi *et al.*³⁾, there was female predilection, with a 1.5:1 female-to-male ratio. The average age was 34 years, with a peak prevalence in the second and third decades of life.

Clinically, schwannoma is a slow-growing tumor that may be present for years before becoming symptomatic²⁾. Swelling is the most common symptom, but pain or paresthesia may also be present in approximately 50% of such cases⁴⁾.

The radiographic appearance of a well-defined unilocular nonspecific radiolucent lesion, with root divergence (expansive growth) and root resorption only in teeth contacting the lesion, was suggestive

of a benign process, and thus making a preoperative diagnosis was difficult. The possibility of an intraosseous schwannoma was not considered at first because of the extreme rarity of this location⁵⁾. The histopathological examination provided a definitive diagnosis for this case.

Histologically, there are two types of tissue arrangement: Antoni-A and B. Alternation between Antoni-A and B regions is common. Antoni-A type is composed of aligned fusiform cells, forming a typical palisade. Between the fibrils there are small eosinophilic masses called Verocay bodies. Antoni-B type is composed of a smaller number of cells and the spindle cells are randomly arranged within a loose myxomatous stroma^{5,6)}. In the present case, Antoni-A type was the predominant microscopic pattern. However, no typical Verocay bodies were identified.

A surgical excision is the treatment of choice and every effort should be made to preserve the integrity of the inferior alveolar nerve whenever possible. In this case, however, the tumor presented with an appearance similar to a twined ball of wool, making preservation or even an incomplete excision impossible. However, a complete excision has a good prognosis due to the low recurrence rate and the rarity of malignant transformation⁷⁾.

REFERENCES

- 1) Fawcett KJ, Dahlin DC : Neurilemmoma of bone. *Am J Clin Path* 47 : 759-766, 1967
- 2) Nakasato T, Katoh K, Ehara S, Tamakawa Y, Hoshino M, Izumizawa M, Sakamaki K, Fukuta Y, Kudoh K : Intraosseous neurilemmoma of the mandible. *AJNR Am J Neuroradiol* 121 : 1945-1947, 2000
- 3) Chi AC, Carey J, Muller S : Intraosseous schwannoma of the mandible: a case report and review of the literature. *Oral Surg Oral Med Oral Pathol Oral Radiol Endod* 96 : 54-65, 2003
- 4) Gallo WJ, Moss M, Shapiro DN, Gaul JV : Neurilemmoma: review of the literature and report of five cases. *J Oral Surg* 35 : 235-236, 1977

- 5) de Lacerda SA, Brentegani LG, Rosa AL, Vespúcio MV, Salata LA : Intraosseous schwannoma of mandibular symphysis: case report. *Braz Dent J* 17 : 255-258, 2006
- 6) Asaumi J, Konouchi H, Kishi K : Schwannoma of the upper lip: ultrasound, CT, and MRI findings. *J Oral Maxillofac Surg* 58 : 1173-1175, 2000
- 7) Kowatsch E, Feichtinger M, Zemmann W, Karpf E, Kärcher H : Extraosseous schwannoma of the mental nerve clinically simulating intraosseous. *J Oral Pathol Med* 35 : 517-519, 2006