



## Ultrasonographic evaluation of geniohyoid muscle mass in perioperative patients

著者	清水 五弥子
著者(英)	Shimizu Sayako
学位名	博士(医学)
学位授与機関	川崎医科大学
学位授与年度	平成28年度
学位授与年月日	2017-03-17
学位授与番号	35303甲第646号
URL	<a href="http://doi.org/10.15111/00001846">http://doi.org/10.15111/00001846</a>

〈Regular Article〉

## Ultrasonographic evaluation of geniohyoid muscle mass in perioperative patients

Sayako SHIMIZU<sup>1)</sup>, Kozo HANAYAMA<sup>1)</sup>, Rui NAKATO<sup>2)</sup>,  
Takefumi SUGIYAMA<sup>1)</sup>, Akio TSUBAHARA<sup>1)</sup>

1) Department of Rehabilitation Medicine, 2) Department of Gastroenterology, Kawasaki Medical School,  
577 Matsushima, Kurashiki, 701-0192, Japan

**ABSTRACT** Surgical invasion and postoperative disuse are known to promote systemic skeletal muscle atrophy; however, similar effects on the mass of the muscles of deglutition have yet to be confirmed. Our method of using ultrasonography to measure the area of the geniohyoid muscle (GM), to evaluate the mass of the muscles of deglutition, has been shown to have high reliability. In the present study, we measured the GM area before and after surgery in patients to investigate changes in their muscle mass. Parameters including GM area, quadriceps femoris muscle (QF) thickness, hand grip strength (HGS), and arm muscle circumference were measured preoperatively and at 7 and 14 days postoperatively in patients who underwent thoracotomy and laparotomy. Patient height, weight, and serum albumin (Alb) level were also obtained from medical charts. Comparison of each evaluation parameter between measurement time points demonstrated significant decreases in GM area, QF thickness, HGS, and Alb between preoperatively and both postoperative day (POD) 7 and POD 14. The patients were divided into good (n = 19) and poor (n = 12) postoperative oral intake groups for comparison of GM area. The percentage decrease in GM area was significantly greater in patients with poor oral intake. To our knowledge, this is the first study to demonstrate that muscle atrophy due to surgical invasion or disuse may occur in the muscles of deglutition, as in the limb muscles. The findings showed that muscle atrophy occurs in the early postoperative period and persists even at 2 weeks postoperatively. Furthermore, insufficient oral intake may promote disuse muscle atrophy.

doi:10.11482/KMJ-E42(2)47 (Accepted on August 25, 2016)

Key words : Ultrasound, Suprahyoid muscle, Surgical invasion, Disuse atrophy, Deglutition

### INTRODUCTION

Surgical patients are known to be at a risk of decreased systemic skeletal muscle mass due to surgical invasion, malnutrition, and disuse. Limb

muscle atrophy reportedly progresses from the early postoperative period as a result of invasion or immobility<sup>1–5)</sup>. Similar decreases in muscle mass could be expected to occur in the muscles

---

Corresponding author  
Sayako Shimizu  
Department of Rehabilitation Medicine, Kawasaki  
Medical School, 577 Matsushima, Kurashiki, 701-0192,  
Japan

Phone : 81 86 462 1111  
Fax : 81 86 464 1186  
E-mail: s-shimizu@med.kawasaki-m.ac.jp

of deglutition. Muscle atrophy due to sarcopenia and disuse is known to cause swallowing impairment<sup>6-12)</sup>; however, no relationships between these conditions and the mass of the muscles of deglutition have been reported. Difficulties in measuring the mass of the muscles of deglutition and the lack of established, convenient methods for bedside evaluation may account for the absence of such studies.

The geniohyoid muscle (GM) is one of the suprahyoid muscles that move the hyoid bone anterosuperiorly during swallowing, contributing to epiglottal inversion and opening of the upper esophageal sphincter, and playing an essential role in swallowing movements<sup>13-16)</sup>. Evaluation of the GM is thus useful for evaluating the muscles of deglutition. Our previously reported method of using ultrasonography to measure the area of the GM, to evaluate the mass of the muscles of deglutition, has been shown to be highly reliable<sup>17)</sup>.

The present study used ultrasonographic evaluation to measure the preoperative and postoperative GM area in order to (i) investigate factors correlating to suprahyoid muscle mass, (ii) verify suprahyoid muscle atrophy resulting from surgical invasion and disuse, and (iii) assess the degree of postoperative muscle mass change and the effects of disuse on the muscles of deglutition.

## METHODS

### Subjects

The subjects comprised surgical patients admitted at Kawasaki Medical School Hospital between January and June 2016, and scheduled to undergo surgery requiring postoperative bed rest and nil-by-mouth status. Specifically, these surgeries comprised thoracotomy involving cardiopulmonary bypass and laparotomy as a radical treatment for esophageal, gastric, small bowel, or colon cancer. Only patients who provided preoperative informed consent for participation and were available for evaluation were

enrolled. Patients who had a preoperative inability to independently perform activities of daily living (ADL) and those with previous dysphagia due to otorhinolaryngological disease or brain and nervous system disorders were excluded.

The present study was approved by the Research Ethics Committee of Kawasaki Medical School Hospital (approval no. 2278).

### Measurements

#### 1. GM area

The area of the GM was measured by using an ultrasound device (SonoSite M-Turbo; FUJIFILM SonoSite, Tokyo, Japan) with the patient positioned

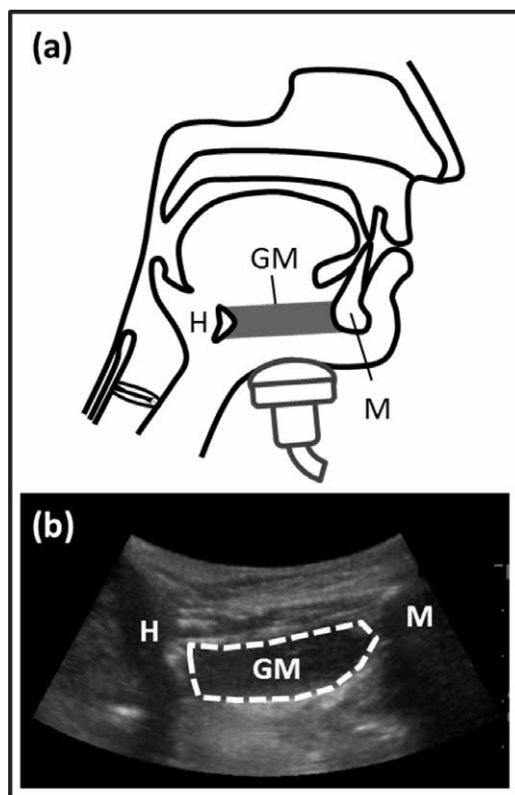


Fig. 1. Ultrasound appearance of the geniohyoid muscle (GM) (a) Position of the ultrasound transducer. (b) Ultrasonic image of the midsagittal plane. The ultrasound transducer was applied in alignment with the midline of the floor of the mouth and perpendicular to the lower chin surface of the patient. The hyoid bone (H) and mandible (M) accompanying the acoustic shadow together with the adhering GM were delineated in the midsagittal plane.

supine on a bed without a pillow. A 2- to 5-MHz convex transducer was applied in alignment with the midline of the floor of the mouth and perpendicular to the lower chin surface of the patient (Fig. 1a). The transducer was positioned at a height that enabled delineation of the hyoid bone while avoiding contact between the face of the probe and the thyroid cartilage. Ultrasound gel was liberally applied, and care was taken to avoid compressing the submental soft tissues. The hyoid bone and the mandible accompanying the acoustic shadow together with the adhering GM at rest were delineated in the midsagittal plane in B-mode (frequency, 3.5 MHz) on a single screen (Fig. 1b). Evaluation was performed three times, and the respective static images were recorded. Measurements were performed on a computer with Image J version 1.43 software (NIH, Bethesda, MD, USA)<sup>18)</sup>. The area enclosing the muscle and fascial boundary of the GM was measured. The mean values of measurements from three images were used for analysis.

## 2. *Quadriceps femoris muscle (QF) thickness*

The QF (comprising the rectus femoris muscle [RF] and vastus medialis muscle [VM]) thickness was measured by using an ultrasound device (SonoSite M-Turbo) with the patient in a supine position with the hip and knee joints extended at 0°. A 15- to 6-MHz linear transducer was applied at the midpoint on a straight line joining the anterior superior iliac spine and superior margin of the patella. The RF, VM, and femur were visualized in sagittal section (B mode; frequency, 10.5 MHz) on one screen (Fig. 2). Ultrasound gel was liberally applied, and care was taken to avoid compressing the soft tissues of the thigh. The transducer was angled in the direction that allowed obtaining maximal echo intensity of the femur. Evaluation was performed three times, and the respective static images were recorded. Measurements were

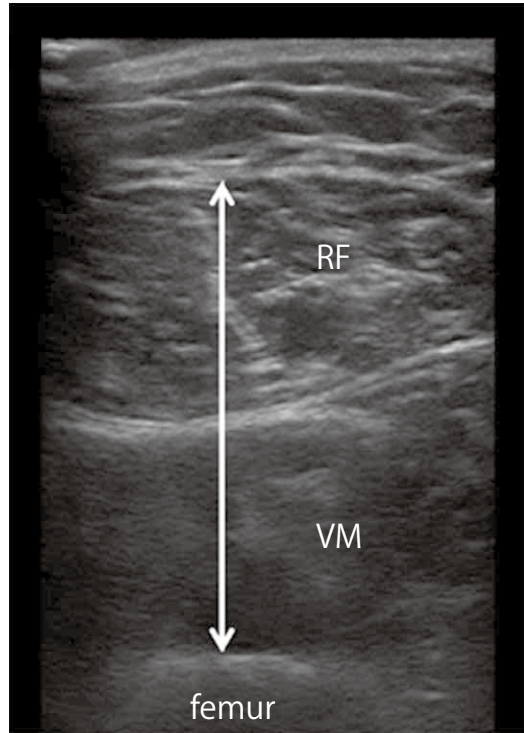


Fig. 2. Ultrasound appearance of the quadriceps femoris muscle (QF)

The ultrasound transducer was applied at the midpoint on a straight line joining the anterior superior iliac spine and the superior margin of the patella. The transducer was angled in the direction that allowed obtaining the maximal echo intensity of the femur. The surface rectus femoris muscle (RF), deep vastus medialis muscle (VM), and the femur were visualized in sagittal section (B mode).

performed on a computer with Image J version 1.43 software. The major axes of the RF and VM were measured perpendicular to the superior margin of the femur. The mean values of measurements from three images were used for analysis.

## 3. *Hand grip strength (HGS)*

The HGS of the dominant hand was measured by using a Grip-A device (Takei Scientific Instruments, Niigata, Japan) with the patient positioned supine, with the shoulder in neutral position and the elbow extended. Measurements were performed twice, and the higher value was used for analysis. Sufficient rest was allowed between measurements.

#### 4. Arm muscle circumference (AMC) and percentage AMC (%AMC)

The AMC was calculated by using the following equation:  $AMC = \text{arm circumference (AC; cm)} - 3.14 \times \text{triceps skinfold (TSF; mm)}$ . Measurements were taken from the left upper arm with the patient positioned supine on a bed. With the elbow flexed at  $90^\circ$ , a mark was made on the arm at the midpoint on a straight line joining the acromion process and the tip of the elbow. The elbow was then extended, and the AC was measured at the level of the mark by using a tape measure. The mean of three measurements was used to calculate the AMC. The TSF was measured at the same level as the AC. The skin on the posterior of the upper arm was pinched and pulled to separate the subcutaneous fat layer from the muscle, and measurements were made by using a subcutaneous fat caliper. The mean of three measurements was used to calculate the AMC.

The %AMC was calculated for the age and sex of the patient based on the 2001 Japanese Anthropometric Reference Data, by using the following equation:  $\%AMC = AMC \div \text{reference AMC value (cm)} \times 100$ .

#### Procedure

The GM area, QF thickness, HGS, and AMC were measured preoperatively (on initial examination at our department) and at 7 and 14 days postoperatively. The patient height, weight, body mass index (BMI), and serum albumin (Alb) level were also obtained from medical charts on the same day of the measurements. If the weight measurements and blood testing were not performed on that day, the findings from within  $\pm 2$  days were used.

#### Analysis

Correlations between the GM area and each evaluation parameter were analyzed to investigate factors correlating with suprahyoid muscle mass.

Each evaluation parameter was then compared among the preoperative, postoperative day (POD) 7, and POD 14 measurements.

The patients were divided into the good and poor oral intake groups based on whether postoperative oral intake had or had not, respectively, returned to the preoperative level within 2 weeks. Intergroup comparison was performed for age, sex, surgery type, and preoperative measurements for all parameters, as well as the postoperative percentage decrease in GM area at POD 7 and POD 14.

#### Statistical analyses

Correlations between evaluation parameters were investigated by using the Pearson correlation coefficient (correlation,  $0.4 < r \leq 0.7$ ; strong correlation,  $0.7 < r < 1.0$ ). One-way repeated-measures analysis of variance was used to compare the evaluation parameters between the three time points (preoperative, POD 7, and POD 14). If a significant difference was identified, post hoc Bonferroni *t*-tests were performed. Intergroup comparisons between the good and poor oral intake groups were performed by using an unpaired *t*-test. Values of  $p < 0.05$  were considered significant. All statistical analyses were performed with SPSS Statistics version 22 (IBM, New York, NY, USA).

## RESULTS

#### Subjects

A total of 44 patients were enrolled (12 women [27.3%], 32 men [72.7%]; mean age,  $72.3 \pm 9.5$  years), after excluding 13 patients who met the following exclusion criteria: preoperative inability to independently perform ADL ( $n = 4$ ) and dysphagia ( $n = 2$ ). Surgery was cancelled in two patients. Five patients were unavailable for the 2-week follow-up after declining to undergo postoperative evaluation ( $n = 1$ ) or being discharged to home or transferred to another hospital before follow-up on POD 14 ( $n = 4$ ). As a result, a total of 31 patients were analyzed.

Thoracotomy was performed in 20 patients (valvulopathy,  $n = 15$ ; aneurysm,  $n = 3$ ; coronary artery disease,  $n = 1$ ; atrial septal defect,  $n = 1$ ), whereas laparotomy was performed in 16 patients (esophageal cancer,  $n = 3$ ; gastric cancer,  $n = 5$ ; and colon cancer,  $n = 8$ ).

#### *GM area and evaluation parameters*

The GM was visualized and found suitable for measurements in all patients. The mean measurements of preoperative evaluation parameters, and the correlation between GM area and each parameter are shown in Table 1. A significant positive correlation was observed between GM area and each of QF thickness, weight, and HGS.

#### *Preoperative and postoperative comparison*

The comparison of evaluation parameters among the preoperative, POD 7, and POD 14 measurements showed a significant difference between the three time points in GM area, QF thickness, HGS, %AMC, Alb level, and BMI. The GM area, QF thickness, HGS, and Alb level showed significant differences between preoperatively and POD 7, whereas %AMC and BMI did not show a significance. Further decline in QF thickness was

observed from POD 7 to POD 14 (Fig. 3).

#### *Intergroup comparisons in postoperative oral intake*

No significant differences were observed between the good oral intake group ( $n = 19$ ; 5 women, 14 men; mean age,  $70.6 \pm 10.1$  years; thoracotomy,  $n = 13$ ; laparotomy,  $n = 6$ ) and the poor oral intake group ( $n = 12$ ; 5 women, 7 men; mean age,  $74.8 \pm 5.3$  years; thoracotomy,  $n = 5$ ; laparotomy,  $n = 7$ ) with regard to age or any preoperative evaluation parameters.

The percentage decreases in GM area in the good and poor oral intake groups were 9.47% and 17.49%, respectively, at POD 7, and 8.58% and 18.30%, respectively, at POD 14. The postoperative percentage decrease in GM area was greater on average in the poor oral intake group than in the good oral intake group, and a significant difference was observed at POD 14 (Fig. 4).

## DISCUSSION

#### *Ultrasound evaluation of suprahyoid muscle mass*

To our knowledge, the present study is the first to longitudinally evaluate the muscle mass in the suprahyoid muscles. In the clinical setting, evaluation of the mass of the muscles of deglutition is not usually performed. The mass of those muscles is only estimated by using indirect methods such as visual examination and palpation, and videofluorography of the hyoid bone and laryngeal movement during swallowing.

Quantitative evaluation of the mass of the muscles of deglutition can be performed by using computed tomography<sup>7)</sup>, magnetic resonance imaging<sup>19)</sup>, and ultrasonography. Among them, ultrasonography has the advantages of being minimally invasive, relatively inexpensive, not restrictive of patient posture, and able to be performed at the bedside. This approach also enables easy visualization of the submental muscles, making it suitable for quantitatively evaluating the mass of the muscles of

Table 1. The correlation between geniohyoid muscle (GM) area and evaluation parameters

	Mean $\pm$ SD	GM area
		<i>r</i>
GM area (cm <sup>2</sup> )	1.97 $\pm$ 0.60	
QF thickness (cm)	2.56 $\pm$ 0.74	0.490**
HGS (kg)	27.51 $\pm$ 10.16	0.540**
Weight (kg)	53.81 $\pm$ 12.46	0.486**
Height (cm)	158.3 $\pm$ 9.81	0.395
BMI (kg/m <sup>2</sup> )	21.17 $\pm$ 4.17	0.320
AMC (cm)	17.45 $\pm$ 8.50	0.236
%AMC (%)	78.16 $\pm$ 38.87	0.121
Alb level (g/dl)	3.58 $\pm$ 0.62	0.320

GM; geniohyoid muscle, QF; quadriceps femoris muscle, HGS; hand grip strength, BMI; body mass index, AMC; percentage arm muscle circumference, Alb; serum albumin  
*r*: Pearson correlation coefficient. \* $p < 0.05$ , \*\* $p < 0.01$ .

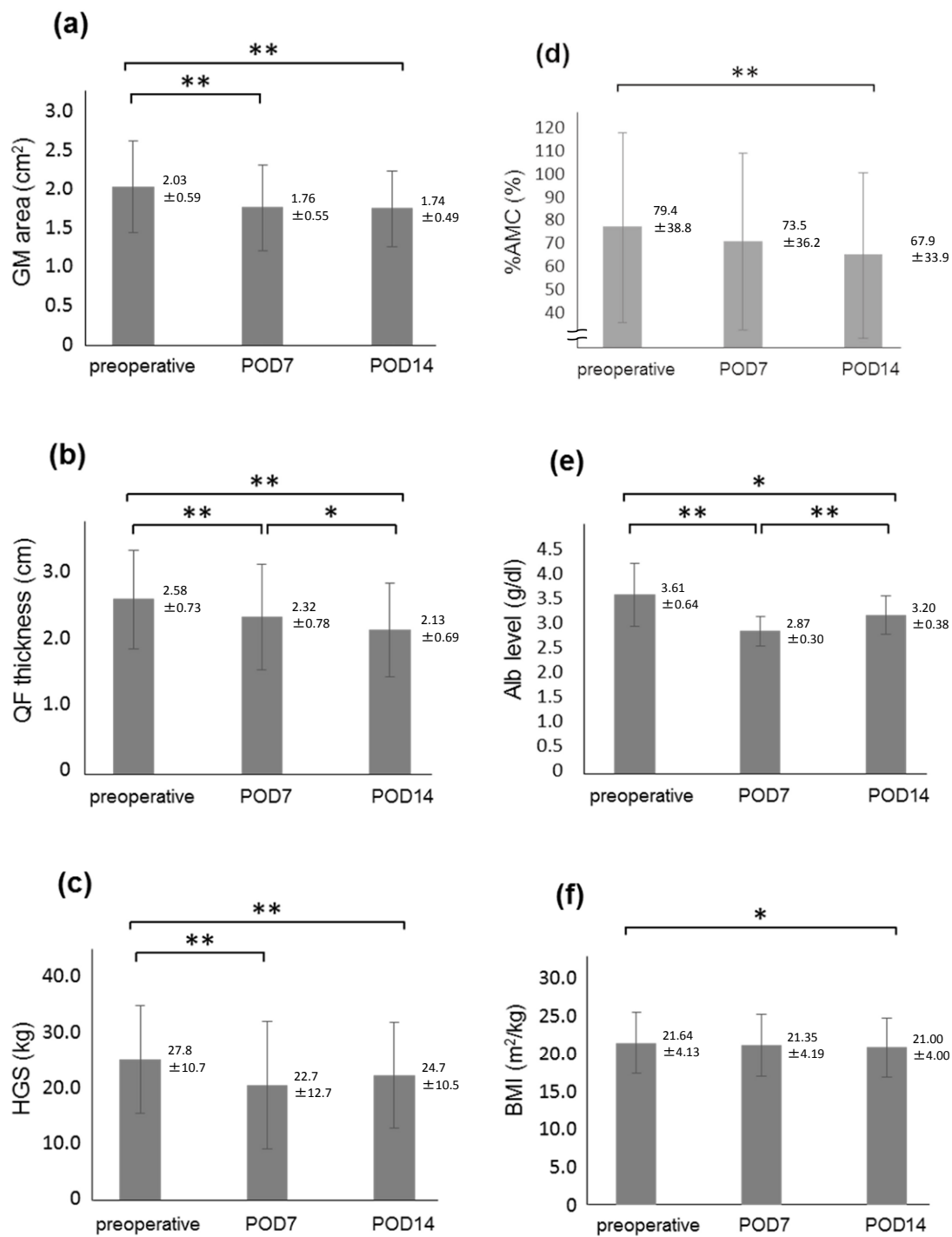


Fig. 3. Postoperative comparison of evaluation parameters. Mean values and standard deviations preoperatively and at postoperative day (POD) 7 and 14 for (a) geniohyoid muscle (GM) area, (b) quadriceps femoris muscle (QF) thickness, (c) hand grip strength (HGS), (d) percentage arm muscle circumference (%AMC), (e) serum albumin (Alb) level, and (f) body mass index (BMI). The three measurement time points were compared by using analysis of variance with post hoc Bonferroni *t*-test. \* $p < 0.05$ , \*\* $p < 0.01$ .

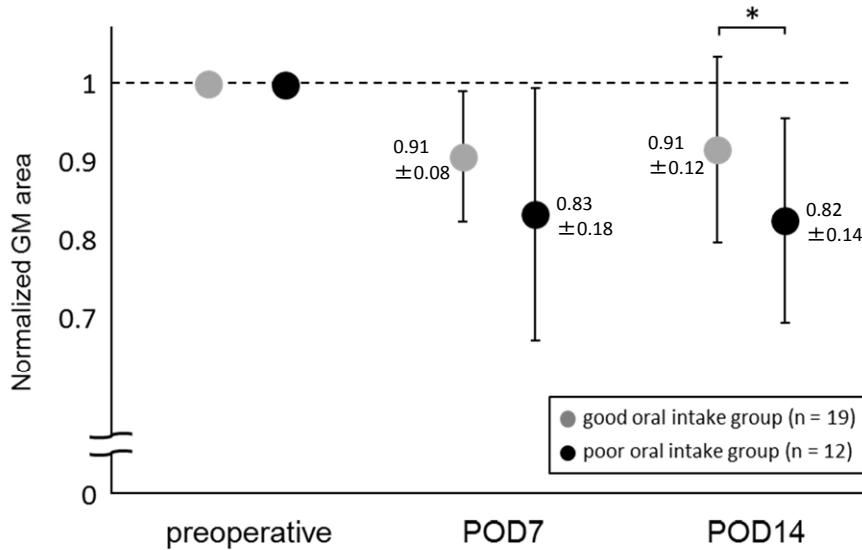


Fig. 4. Postoperative geniohyoid muscle (GM) area

Measurements at postoperative day (POD) 7 and 14 for the GM area are shown normalized to preoperative measurements. The percentage decreases in the GM area in the good and poor oral intake groups were 9.47% and 17.49% between preoperatively and POD 7, and 8.58% and 18.30% between preoperatively and POD 14. Intergroup comparisons between the good and poor oral intake groups were performed by using unpaired  $t$ . \* $p < 0.05$ , \*\* $p < 0.01$ .

deglutition.

#### Significance of muscle mass evaluation

The QF thickness and cross-sectional area were reported to correlate with leg muscle strength and muscular performance<sup>20–22</sup>. Skeletal muscle mass serves as an indicator of physical functioning, and this may hold true for the muscles of deglutition. Feng *et al.*<sup>6</sup>) reported a correlation between the GM cross-sectional area and the distance of hyoid bone movement during swallowing. Furthermore, the GM cross-sectional area is reportedly smaller in patients who experienced aspiration<sup>7</sup>). These studies demonstrated the relationship between suprahyoid muscle mass and swallowing function, and indicated the importance of measuring the area of the GM, one of the suprahyoid muscles, when evaluating the mass of the muscles of deglutition.

#### Factors correlating with suprahyoid muscle mass

According to Feng *et al.*<sup>6</sup>), the GM cross-

sectional area correlates positively with physical height. Although no correlation between GM area and physical height was found in the present study, a positive correlation was observed between QF thickness and weight, indicating a possible correlation between suprahyoid and systemic skeletal muscle mass. The GM area also correlated positively with the HGS. The HGS is an indicator not only of arm strength and function but also of systemic muscle strength and physical functioning<sup>23, 24</sup>). Many studies have reported the relationship between HGS and both of swallowing function and the strength of the muscle of deglutition. Hathaway *et al.*<sup>25</sup>) measured the HGS and evaluated swallowing function by using videofluorography, and found a relationship between decreased HGS and impaired swallowing function. Meanwhile, Butler *et al.*<sup>26</sup>) and Mendes *et al.*<sup>27</sup>) reported that decreased systemic muscle strength may cause impairment of deglutition based on a positive correlation between HGS and



lingual pressure. However, the relationship between HGS and suprahyoid muscle mass has not been investigated. The relationship between HGS and suprahyoid muscle mass observed in the present study demonstrated that the suprahyoid muscle mass may also be decreased in patients with systemic decrease in muscle strength and/or physical function.

#### *Changes in postoperative suprahyoid muscle mass*

Invasive surgery causes elevations in inflammatory cytokine levels, and hypermetabolism. In addition, disuse due to bed rest and nil-by-mouth status is also known to cause systemic skeletal muscle atrophy (secondary sarcopenia or disuse muscle atrophy). Gruther *et al.*<sup>1)</sup> found that muscle mass in patients in the intensive care unit rapidly decreased after admission because of invasion and disuse. Furthermore, disuse atrophy occurred rapidly in the first week of immobility<sup>2)</sup>. The present findings similarly showed that the GM area, QF thickness, and HGS decreased rapidly from POD 7, indicating progression of muscular atrophy from an early postoperative stage.

The GM area, QF thickness, HGS, AMC, %AMC, Alb level, and BMI remained significantly lower at POD 14 than their preoperative values. Additionally, patients with insufficient postoperative oral intake displayed a greater percentage decrease in the GM area at POD 14. These findings suggest that the effects of surgical invasion persist beyond 2 weeks after surgery. Furthermore, disuse of the muscles of deglutition caused by decreased oral intake may exacerbate and delay recovery from postoperative muscle atrophy. To prevent disuse, early activities at the postoperative period are known to be effective. However, postoperative patients do not always return to their early oral intake; thus, it would be useful to investigate effective exercises for the muscle of deglutition than can be performed even at nil-by-mouth status.

Ng *et al.*<sup>4)</sup> reported that elevated inflammatory response and decreased muscular performance due to surgical invasion persisted for at least 1 month postoperatively. As the present subjects comprised hospital inpatients, their postoperative evaluation was limited to 2 weeks. Further long-term evaluation of discharged patients is required to investigate the postoperative recovery process.

#### *Limitations*

The present study investigated patients undergoing major surgery who were predicted to require postoperative bed rest and a nil-by-mouth status. As the disease and surgery type were not controlled for, the findings may have been affected by various factors.

#### **SUMMARY**

The present study measured the area of the GM, a suprahyoid muscle, to evaluate the mass of the muscles of deglutition. Suprahyoid muscle mass correlated with systemic skeletal muscle mass, muscle strength, and physical functioning. Skeletal muscle atrophy due to surgical invasion was shown to occur from the early postoperative period and to affect the muscles of deglutition. The present findings also suggest that use of the muscles of deglutition also affects the process of muscle mass atrophy after invasive surgery.

#### **ACKNOWLEDGEMENTS**

This study was supported by JSPS KAKENHI Grant Number 15K01402.

#### **CONFLICT OF INTEREST**

There is no conflict of interest in this study. The authors have no conflict of interest directly relevant to the content to this article.

#### **REFERENCES**

- 1) Gruther W, Benesch T, Zorn C, Paternostro-Sluga T,

- Quittan M, Fialka-Moser V, Spiss C, Kainberger F, Crevenna R: Muscle wasting in intensive care patients: ultrasound observation of the M. quadriceps femoris muscle layer. *J Rehabil Med* 40: 185-189, 2008
- 2) Suetta C, Hvid LG, Justesen L, Christensen U, Neergaard K, Simonsen L, Ortenblad N, Magnusson SP, Kjaer M, Aagaard P: Effects of aging on human skeletal muscle after immobilization and retraining. *J Appl Physiol* (1985) 107: 1172-1180, 2009
  - 3) Bautmans I, Njemini R, De Backer J, De Waele E, Mets T: Surgery-induced inflammation in relation to age, muscle endurance, and self-perceived fatigue. *J Gerontol A Biol Sci Med Sci* 65: 266-273, 2010
  - 4) Ng YC, Lo NN, Yang KY, Chia SL, Chong HC, Yeo SJ: Effects of periarticular steroid injection on knee function and the inflammatory response following Unicondylar Knee Arthroplasty. *Knee Surg Sports Traumatol Arthrosc* 19: 60-65, 2011
  - 5) Wall BT, Dirks ML, van Loon LJ: Skeletal muscle atrophy during short-term disuse: implications for age-related sarcopenia. *Ageing Res Rev* 12: 898-906, 2013
  - 6) Feng X, Cartwright MS, Walker FO, Bargoil JH, Hu Y, Butler SG: Ultrasonographic evaluation of geniohyoid muscle and hyoid bone during swallowing in young adults. *Laryngoscope* 125: 1886-1891, 2015
  - 7) Feng X, Todd T, Lintzenich CR, Ding J, Carr JJ, Ge Y, Browne JD, Kritchevsky SB, Butler SG: Aging-related geniohyoid muscle atrophy is related to aspiration status in healthy older adults. *J Gerontol A Biol Sci Med Sci* 68: 853-860, 2013
  - 8) Yabunaka K, Konishi H, Nakagami G, Sanada H, Iizaka S, Sanada S, Ohue M: Ultrasonographic evaluation of geniohyoid muscle movement during swallowing: a study on healthy adults of various ages. *Radiol Phys Technol* 5: 34-39, 2012
  - 9) Tamura F, Kikutani T, Tohara T, Yoshida M, Yaegaki K: Tongue thickness relates to nutritional status in the elderly. *Dysphagia* 27: 556-561, 2012
  - 10) Yabunaka K, Sanada H, Sanada S, Konishi H, Hashimoto T, Yatake H, Yamamoto K, Katsuda T, Ohue M: Sonographic assessment of hyoid bone movement during swallowing: a study of normal adults with advancing age. *Radiol Phys Technol* 4: 73-77, 2011
  - 11) Maeda K, Akagi J: Decreased tongue pressure is associated with sarcopenia and sarcopenic dysphagia in the elderly. *Dysphagia* 30: 80-87, 2015
  - 12) Logemann JA, Pauloski BR, Rademaker AW, Colangelo LA, Kahrilas PJ, Smith CH: Temporal and biomechanical characteristics of oropharyngeal swallow in younger and older men. *J Speech Lang Hear Res* 43: 1264-1274, 2000
  - 13) Steele CM, Bailey GL, Chau T, Molfenter SM, Oshalla M, Waito AA, Zoratto DC: The relationship between hyoid and laryngeal displacement and swallowing impairment. *Clin Otolaryngol* 36: 30-36, 2011
  - 14) Ekberg O, Sigurjónsson SV: Movement of the epiglottis during deglutition. A cineradiographic study. *Gastrointest Radiol* 7: 101-107, 1982
  - 15) Kendall KA, Leonard RJ: Hyoid movement during swallowing in older patients with dysphagia. *Arch Otolaryngol Head Neck Surg* 127: 1224-1229, 2001
  - 16) Pearson WG Jr, Langmore SE, Zumwalt AC: Evaluating the structural properties of suprahyoid muscles and their potential for moving the hyoid. *Dysphagia* 26: 345-351, 2011
  - 17) Shimizu S, Hanayama K, Metani H, Sugiyama T, Abe H, Seki S, Hiraoka T, Tsubahara A: Retest reliability of ultrasonic geniohyoid muscle measurement. *Jpn J Compr Rehabil Sci* 7: 55-60, 2016
  - 18) Rasband, W.S, ImageJ, U.S. National Institutes of Health, Bethesda, Maryland, USA, <http://rsb.info.nih.gov/ij/>, 1997-2012
  - 19) Macrae PR, Jones RD, Myall DJ, Melzer TR, Huckabee ML: Cross-sectional area of the anterior belly of the digastric muscle: comparison of MRI and ultrasound measures. *Dysphagia* 28: 375-380, 2013
  - 20) Ikezoe T, Asakawa Y, Fukumoto Y, Tsukagoshi R, Ichihashi N: Associations of muscle stiffness and thickness with muscle strength and muscle power in elderly women. *Geriatr Gerontol Int* 12: 86-92, 2012
  - 21) Chi-Fishman G, Hicks JE, Cintas HM, Sonies BC, Gerber LH: Ultrasound imaging distinguishes between normal and weak muscle. *Arch Phys Med Rehabil* 85: 980-986, 2004
  - 22) Giles LS, Webster KE, McClelland JA, Cook J: Can ultrasound measurements of muscle thickness be used to measure the size of individual quadriceps muscles in people with patellofemoral pain? *Phys Ther Sport* 16: 45-52, 2015
  - 23) Rantanen T, Era P, Kauppinen M, Heikkinen E: Maximal Isometric Muscle Strength and Socioeconomic Status, Health, and Physical Activity in 75-Year-Old Persons. *J*

- Aging Phys Act 2: 206-220, 1994
- 24) Rantanen T, Guralnik JM, Foley D, Masaki K, Leveille S, Curb JD, White L: Midlife hand grip strength as a predictor of old age disability. *JAMA* 281: 558-560, 1999
- 25) Hathaway B, Baumann B, Byers S, Wasserman-Wincko T, Badhwar V, Johnson J: Handgrip strength and dysphagia assessment following cardiac surgery. *Laryngoscope* 125: 2330-2332, 2015
- 26) Butler SG, Stuart A, Leng X, Wilhelm E, Rees C, Williamson J, Kritchevsky SB: The relationship of aspiration status with tongue and handgrip strength in healthy older adults. *J Gerontol A Biol Sci Med Sci* 66: 452-458, 2011
- 27) Mendes AE, Nascimento L, Mansur LL, Callegaro D, Jacob Filho W: Tongue forces and handgrip strength in normal individuals: association with swallowing. *Clinics (Sao Paulo)* 70: 41-45, 2015