

〈Case Report〉

Severe hyperkalemia following ileostomy not colostomy in a patient undergoing chronic hemodialysis

Daisuke YORIMITSU, Tamaki SASAKI, Hideyuki HORIKE, Takaaki FUEKI,
Souhachi FUJIMOTO, Norio KOMAI, Minoru SATOH, Naoki KASHIHARA

*Department of Nephrology and Hypertension, Kawasaki Medical School,
577 Matsushima, Kurashiki, 701-0192, Japan*

ABSTRACT In patients with end-stage renal disease (ESRD), the intestinal tract may assume an accessory potassium (K^+) excretory role in the face of declining renal excretory function. Here, we report the case of a patient with ESRD who developed severe hyperkalemia following ileostomy not colostomy. A 6△-year-old woman undergoing hemodialysis began developing severe hyperkalemia after ileostomy. Previously, she had successfully undergone resection and colostomy of the transverse colon. The pre-dialysis serum K^+ level was normal. Our present case demonstrates the importance of intestinal K^+ secretion, especially in the colon, for maintaining hemostasis in patients with ESRD.

doi:10.11482/KMJ-E41(2)65 (Accepted on October 23, 2015)

Key words : Hyperkalemia, Ileostomy, Hemodialysis

INTRODUCTION

Potassium (K^+) is the second most abundant cation in the body. Only 2% of the total-body K^+ is located in the extracellular fluid compartment. The serum K^+ concentration is determined by the relationship between the K^+ intake and the distribution of K^+ between cells, and the extracellular fluid and urinary K^+ excretion. The body has a marked ability to protect against disturbances in K^+ metabolism. However, disorders of K^+ metabolism are common in patients with chronic kidney disease, especially in those undergoing long-term hemodialysis (HD)¹⁾. Furthermore, in long-term HD patients,

hyperkalemia has been associated with a higher mortality^{2,3)}. Under normal conditions, healthy individuals absorb most of the K^+ they ingest from their diet, and they excrete an equal amount in the urine. When severe renal dysfunction supervenes, severe hyperkalemia is expected. However, severe hyperkalemia does not develop. Earlier studies⁴⁾ have demonstrated that intestinal excretion of K^+ increases in severe renal dysfunction, and it may play an important role in reducing K^+ retention.

Here, we report on a case of severe hyperkalemia following ileostomy not colostomy in a patient undergoing chronic HD, and discuss the possible

Corresponding author
Tamaki Sasaki
Department of Nephrology and Hypertension,
Kawasaki Medical School, 577 Matsushima, Kurashiki,
701-0192, Japan

Phone : 81 86 462 1111
Fax : 81 86 462 1199
E-mail: tsasaki@med.kawasaki-m.ac.jp

pathophysiological mechanisms to account for this clinical finding.

CASE REPORT

A 6△-year-old woman began HD in 199X for endstage renal failure due to chronic glomerulonephritis. In February 200X, the patient was admitted to the Department of Digestive Surgery at our hospital because of a perforated transverse colon. She successfully underwent resection and colostomy of the transverse colon, resumed outpatient dialysis treatment afterwards. In October 200X, the patient was readmitted for ileal perforation due to intestinal obstruction, and she underwent resection of the ascending colon, followed by ileostomy. A stoma was constructed approximately 70 cm from the terminal ileum, and the rectal side stump was closed. Despite an uneventful postoperative course, the patient began to develop severe hyperkalemia postoperatively. Although she had regular HD, the pre-dialysis serum K^+ elevated soon after each HD. She had no remarkable symptoms or signs of hyperkalemia.

She was admitted to our hospital to assess for the severe hyperkalemia. Results of the physical examination were as follows: height, 163 cm; weight, 36.5 kg; blood pressure, 120/60 mmHg; heart rate, 68 beats/min; and respiratory rate, 16 breaths/min. Her skin was dry, and palpebral conjunctiva showed signs of mild anemia. No cardiopulmonary abnormalities were observed. Two stomas were noted on the abdominal wall. Although the ileostomy caused loose stools, only a small amount of intestinal fluid, but no passage, appeared from the stoma of the transverse colon. The patient had undergone uncomplicated HD for 4 hours three times a week, and dialysis parameters included blood flow of 200 mL/min and Kt/V of 1.96 using a VPS-13HA dialyzer (Asahi Kasei Medical Co, Osaka City, Japan). Despite being anuric, the patient's interdialytic

Table 1. Laboratory data on admission K, potassium.

Hematology		
WBC	5,930	/mL
RBC	261×10^4	/mL
Hb	9.8	g/dL
Ht	29.9	%
Plt	13.2×10^4	/mL
Biochemistry		
TP	6.0	g/dL
Glu	124	mg/dL
AIP	232	IU/L
T-Cho	99	mg/dL
LDH	168	g/dL
Alb	3.1	g/dL
ChE	161	IU/L
ALT	4	IU/L
AST	11	IU/L

Table 2. Changes in the metabolic status before and after hemodialysis

	Pre-dialysis	Post-dialysis	Unit
Cm	7.86	2.04	mg/dL
BUN	67	15	mg/dL
UA	7.7	1.5	mg/dL
Na	136	138	mEq/L
K	6.6	3.5	mEq/L
Cl	107	102	mEq/L
P	3.5	1.4	mg/dL
Ca	8.4	9.1	mg/dL
pH	7.355	7.444	
HCO ₃ ⁻	18.8	27.4	mEq/L

weight gain was 1-2 kg. Hemodynamics during dialysis were stable; however, laboratory findings were remarkable for severe hyperkalemia (Tables 1, 2). Despite high serum potassium levels, there were no signs of muscle weakness. In addition, we did not observe characteristic peaked T waves, widened QRS with absent P waves, or sine-wave patterns on electrocardiogram. To exclude the possibility that HD was not sufficiently removing K^+ , that serum K^+ levels were examined before and after HD. We confirmed serum K^+ significantly decreased after each HD session. Additionally, the results of blood gas analysis showed no evidence of severe metabolic acidosis as a potential cause of hyperkalemia. We again instructed the patient

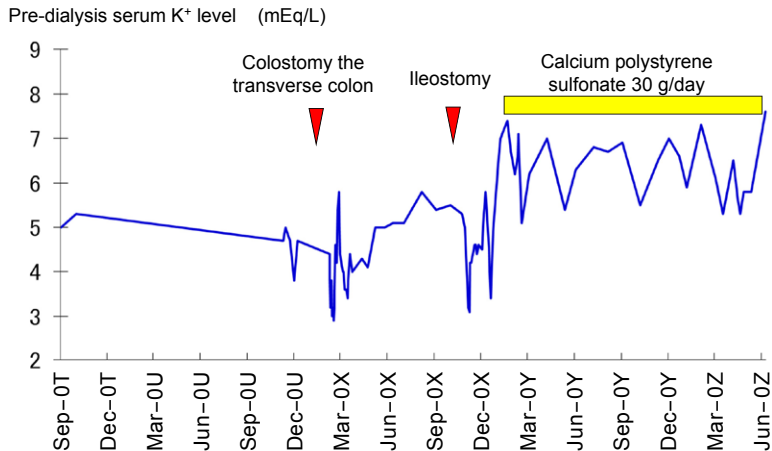


Fig. 1. The clinical course. The patient began to develop severe hyperkalemia after ileostomy. WBC, white blood cell; RBC, red blood cell; Hb, hemoglobin; Ht, hematocrit; Plt, platelet; TP, total protein; Glu, glucose; ALP, alkaline phosphatase; T-Cho, total cholesterol; LDH, lactate dehydrogenase; Alb, albumin; ChE, cholinesterase; ALT, alanine aminotransferase; AST, aspartate aminotransferase.

to avoid ingesting high K^+ foods such as starfruit, bananas, oranges, raisins, and various vegetables. Even with the aforementioned management, hyperkalemia was still noted before the next HD session. Despite the restriction of K^+ and the administration of calcium polystyrene sulfonate (30 g/day), pre-dialysis K^+ levels continued to be around 6 mEq/L. These findings strongly suggested that severe hyperkalemia in our patient was caused by ileostomy not colostomy, and therefore colonic K^+ secretion was significantly reduced (Fig. 1).

DISCUSSION

In this report, we present a case of severe hyperkalemia in a patient with ESRD and anuria who underwent chronic HD. Our patient had a well-controlled stable pre-dialysis K^+ level prior to ileostomy. We assumed that ileostomy was the etiology of hyperkalemia.

Data obtained from patients with varying degrees of renal failure have suggested that increased fecal K^+ begins to contribute to maintaining the K^+ balance when the glomerular filtration rate decreases below 5 mL/min. This is the same point at which residual nephrons develop their maximal

capacity to secrete K^+ into the urine⁴⁾. Intestinal excretion is caused by an increased net K^+ secretion in the colon, and not a reduction in K^+ absorption⁵⁾. A previous study reported that the colon removed up to 30-40 % of K^+ ⁴⁾. Hayes *et al.*^{6,7)} reported metabolic balance studies on patients with HD and found that fecal K^+ excretion was abnormally high. Several patients excreted >50 mEq/day in their stool. Dialysis patients are also known to sweat higher amounts of K^+ than normal, suggesting that various mechanisms are recruited to compensate for a reduction in urinary K^+ excretion. However, the mechanism of enhanced fecal K^+ excretion is not completely understood.

We calculated the K^+ balance in the present case. The daily K^+ intake in healthy individuals is 80-100 mEq. Dialysis patients should restrict their K^+ intake to 40-60 mEq per day, and 40-120 mEq/L (1.5 mEq/kg) of K^+ are usually removed within 3-5 hours of HD, with an additional 0.3 mEq/kg/day of K^+ excreted in the feces. Sodium polystyrene sulfonate is sometimes used in the clinical field. An HD patient with anuria and the same weight as our case removes 54.75 mEq of K^+ per dialysis session (1.5 mEq/kg \times 36.5 kg) or 164.25 mEq

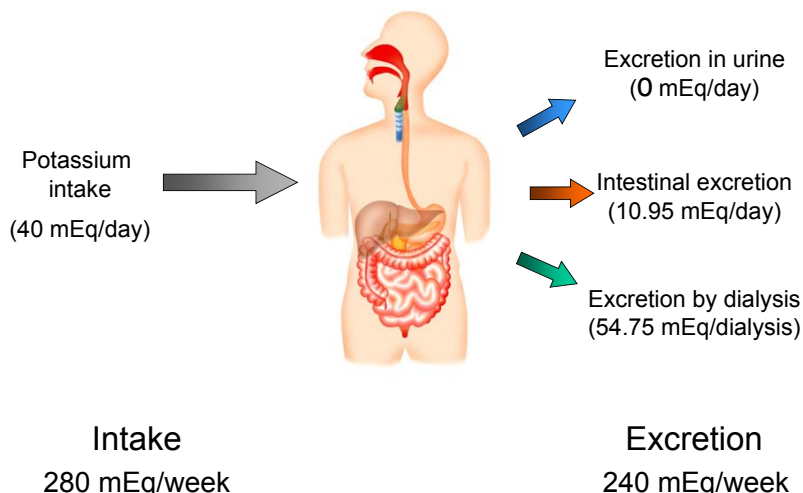


Fig. 2. K^+ balance in the dialysis patient (body weight, 36.5 kg). Crn, creatinine; BUN, blood urea nitrogen; UA, urine analysis; Na, sodium; K, potassium; Cl, chlorine; P, potassium; Ca, calcium; HCO_3^- , bicarbonate.

per week. In addition, the intestinal tract excretes 10.95 mEq/day of K^+ ($0.3 \text{ mEq/kg} \times 36.5 \text{ kg}$) or 76.65 mEq/week of K^+ in the feces. Therefore, our case excreted approximately 240 mEq of K^+ weekly, which is similar to the amount of K^+ intake per week (Fig. 2). However, the present patient could not excrete K^+ via the intestinal tract, and she was overloaded with 10.95 mEq/day of K^+ . Based on the assumption that the amount of the extracellular fluid was 7.3 L, the serum K^+ level would increase by approximately 1.5 mEq/L per day (i.e., 3.0 mEq/L between dialysis sessions provided every other day). This value matches recent laboratory findings and strongly suggests that the continuously severe K^+ in the present case was caused by impaired excretion of K^+ through the intestinal tract, especially the colon. A previous case report⁸⁾ showed severe hyperkalemia following colon diversion surgery in a maintenance hemodialysis patient. As for the cause of the hyperkalemia, the involvement of reduced colon K^+ secretion was suspected due to temporary ileostomy. After the bowel continuity was restored, hyperkalemia improved. This case also is consistent with our deliberations.

CONCLUSIONS

Our case demonstrates the importance of intestinal K^+ secretion, especially in the colon, for maintaining of hemostasis in patients with ESRD. The clinical course of the present patient helped elucidate the importance of K^+ excretion via the gastrointestinal tract, especially in the colon, in patients with impaired renal function.

REFERENCES

- 1) Lowrie EG, Huang WH, Lew NL: Death risk predictors among peritoneal dialysis and hemodialysis patients: a preliminary comparison. *Am J Kidney Dis* 26: 220-228, 1995
- 2) Iseki K, Uehara H, Nishime K, Tokuyama K, Yoshihara K, Kinjo K, Shiohira Y, Fukiyama K: Impact of the initial levels of laboratory variables on survival in chronic dialysis patients. *Am J Kidney Dis* 28: 541-548, 1996
- 3) Kovesdy CP, Regidor DL, Mehrotra R, Jing J, McAllister CJ, Greenland S, Kopple JD, Kalantar-Zadeh K: Serum and dialysate potassium concentrations and survival in hemodialysis patients. *Clin J Am Soc Nephrol* 2: 999-1007, 2007
- 4) Agarwal R, Afzalpurkar R, Fordtran JS: Pathophysiology of potassium absorption and secretion by the human

- intestine. *Gastroenterology* 107: 548-571, 1994
- 5) Martin RS, Panese S, Virginillo M, Gimenez M, Litardo M, Arrizurieta E, Hayslett JP. Increased secretion of potassium in the rectum of humans with chronic renal failure. *Am J Kidney Dis* 8:105-110, 1986
 - 6) Hayes CP Jr, Robinson RR: Fecal potassium excretion in patients on intermittent hemodialysis. *Trans Am Soc Artif Intern Organs* 11: 242-246, 1965
 - 7) Hayes CP Jr, McLeod ME, Robinson RR: An extrarenal mechanism for the maintenance of potassium balance in severe chronic renal failure. *Trans Assoc Am Physicians* 80: 207-216, 1967
 - 8) Kononowa N, Dickenmann MJ, Kim MJ: Severe hyperkalemia following colon diversion surgery in a patient undergoing chronic hemodialysis: a case report. *J Med Case Rep* 7: 207, 2013

