

# Reconstruction of the Tragus Using a Pedicled Chondrocutaneous Flap

Hiroaki OKA, Yasuhiro YAMAMOTO, Haruyuki TAKADA, Shogo EBISUDANI and Takahiko MORIGUCHI

*Department of Plastic and Reconstructive Surgery, Kawasaki Medical School :  
577 Matsushima Kurashiki, Okayama, 701-0192 Japan*

*Accepted for publication on January 29, 2007*

**ABSTRACT.** A 40-year-old woman had her left tragus excised 10 years earlier because of a benign skin tumor. A pedicled chondrocutaneous flap was designed on the left auricle. The flap has survived and the patient has been provided with a good appearance. Therefore we believe that this pedicled flap might possibly be used in reconstruction of the external auditory meatus.

**Key words** ① **Tragus** ② **Chondrocutaneous flap** ③ **Pedicled flap**  
④ **Ear deformity**

There have been many reports of reconstruction of the tragus in microtia<sup>1),4),5)</sup>, but few reports of simple reconstruction of a defect of the tragus due to tumor resection or trauma. There have been several recent reports<sup>2),7),9)</sup> on the use of chondrocutaneous flaps of the auricle as a result of a detailed study of its arterial supply by Park *et al*<sup>6)</sup>. According to these previous reports, the chondrocutaneous flaps were used as free vascularized flaps to reconstruct the nose and the trachea. In this case, we employed a pedicled chondrocutaneous flap from the concha-helix for reconstruction of the tragus.

## CASE REPORT

The present case was a 40-year-old woman whose left tragus had been excised 10 years earlier at another hospital because of a benign skin tumor (Fig.1). We were unable to obtain a pathologic diagnosis for this tumor. Because she had a hearing disturbance, the defect in her tragus made it difficult for her to wear a hearing aid. To reconstruct the tragus, a chondrocutaneous flap including the helix was designed on the anterior and posterior aspects of her left auricle. Specifically, the flap was designed to include the subcutaneous vessel on the posterior surface of the auricle (Fig.2). We chose the left superficial temporal artery for the pedicle of the flap (Fig.3a), but did not dissect the left superficial temporal vein to preserve the anterior and posterior arterial network of the left auricle. Additional skin from the left temporal area was included for venous drainage of the flap. A free skin graft from the groin area with a width of 1cm and a length of 3cm was made on the left temporal region. The chondrocutaneous flap was transferred to the defect of the tragus (Fig.3b). Although slight venous congestion was seen in the flap on the first day after the operation (Fig. 4a), most of the flap survived (Fig. 4b). The pedicle of the flap was severed three months later

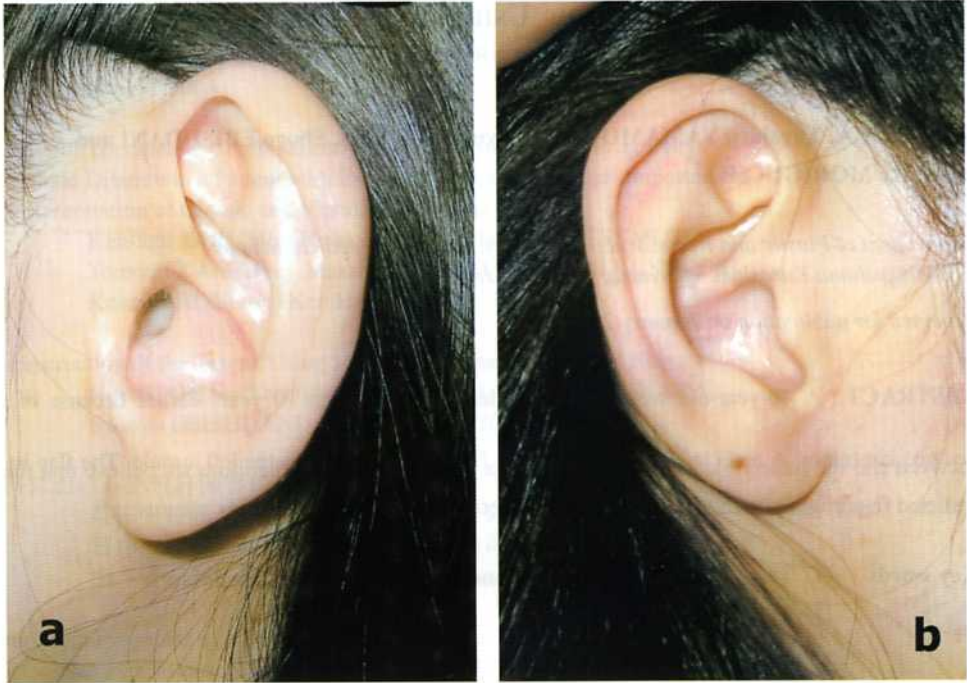


Fig. 1. (a) Preoperative appearance of the left auricle with a defect of the tragus. The external auditory canal of the left auricle could be clearly seen. (b) The external auditory canal of the right auricle, which was normal, could not be seen.

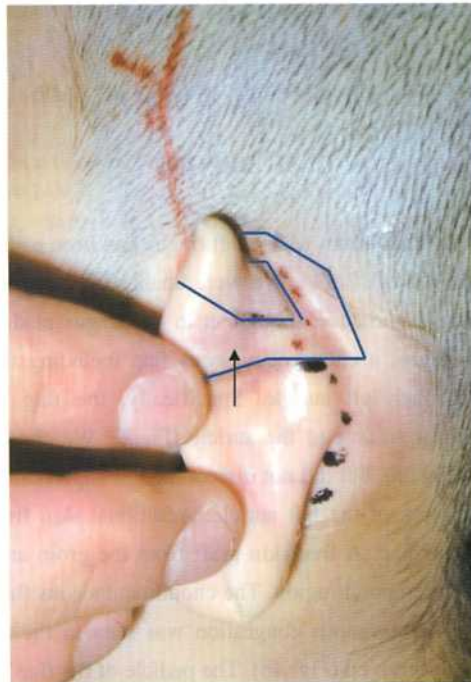


Fig. 2. Design of the left chondrocutaneous flap. The red line indicates the superficial temporal artery. The arrow shows the subcutaneous vessels.



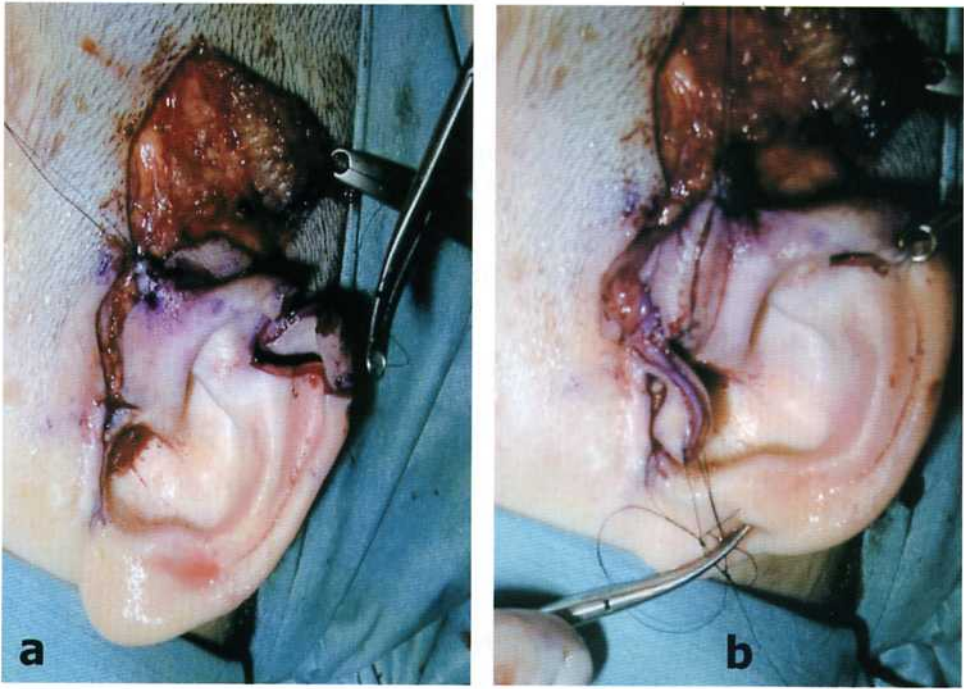


Fig. 3. Operative view. (a)The chondrocutaneous flap was elevated with the branch of the superficial temporal artery. (b)The flap was transferred.

(Fig. 5a). The tragus now has a good cosmetic appearance and the patient can comfortably wear her hearing aid(Fig. 5b).

## DISCUSSION

In microtia, the tragus is usually reconstructed with a cartilage framework<sup>1),4),5)</sup>. However, it is very difficult to reconstruct a defect of the tragus due to trauma or tumor excision. Although a non-vascularized composite graft is an effective method for reconstruction of the tragus<sup>8)</sup>, its survival is influenced by the surrounding vascular state. A non-vascularized composite graft is particularly unsuitable for scar tissue due to trauma or tumor resection. Martinez *et al*<sup>3)</sup> reported that the tragus could be reconstructed with a pedicled flap using the ear lobule, but ear cartilage was not included in this flap. Since our patient had requested surgical treatment of her tragus defect because of difficulty in wearing a hearing aid, we considered that a flap including cartilage was needed for reconstruction of the tragus. Parkhouse *et al*<sup>7)</sup> reported reconstruction of the nasal ala using a composite free pinna flap, based on the cadaveric observation that the helix receives a direct cutaneous branch of the superficial temporal artery. Park *et al*<sup>6)</sup> clearly defined the arterial supply of the anterior ear. Based on these reports, a full thickness chondrocutaneous flap was safely elevated<sup>2),9),10)</sup>. However, because there was a strong possibility of unstable venous drainage from a small chondrocutaneous flap from the helix, additional skin from the left temporal area was included for venous drainage and transferred to the defect of the tragus. As a result, the flap became bulky and skin grafting to the temporal region was required. It has been reported that the external diameter of the upper auricular branch of the

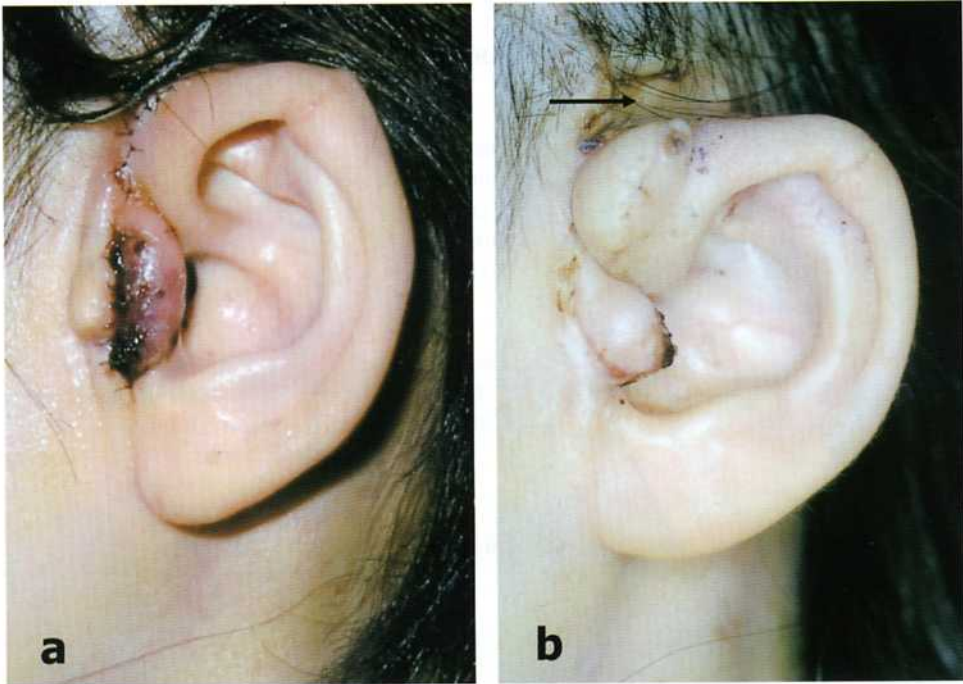


Fig. 4. (a) Venous congestion of the flap was seen on the first postoperative day. (b) Bulkiness of the pedicle of the flap was seen on the fourteenth postoperative day. The arrow indicates the skin graft on the left temporal region.

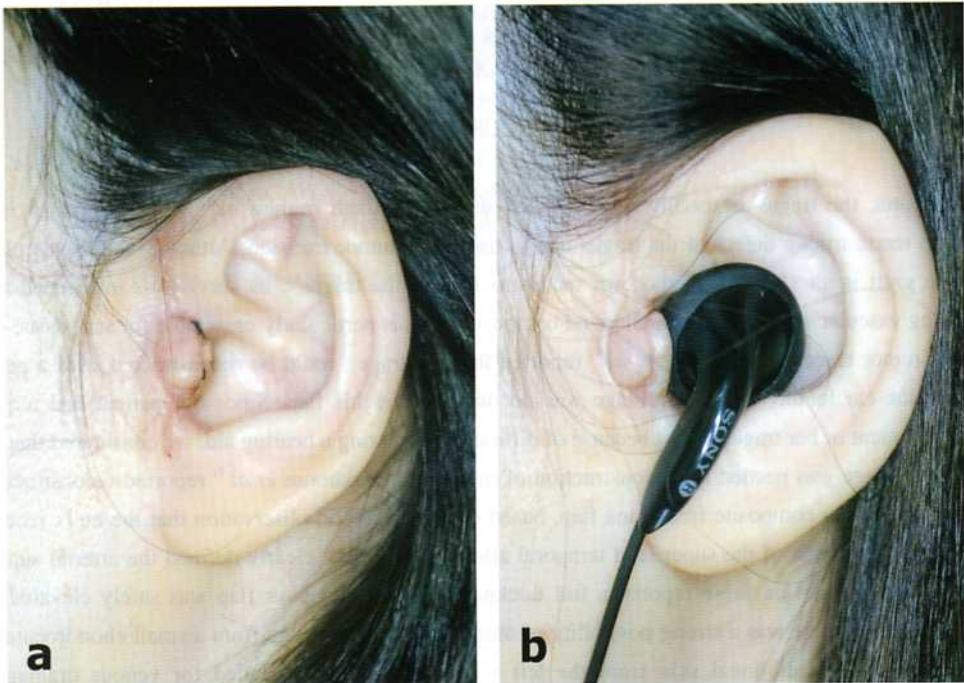


Fig. 5 (a) Three months after the first operation, the pedicle of the flap was excised. (b) Nine months after the first operation, a hearing aid was placed in the left auricle.

superficial temporal artery is only about 1.0 mm<sup>6)</sup>, but there is no information regarding the venous system of the auricle. Koshima *et al*<sup>2)</sup> and Tanaka *et al*<sup>9)</sup> reported that slight venous congestion was seen after a chondrocutaneous free flap was transferred. We believe that dissection of the pinna should be a minimally invasive procedure. Attention should be paid to including enough skin and subcutaneous tissue. The bulkiness of this flap should be trimmed secondarily to attain a safe result.

## REFERENCES

- 1) Brent B : Technical advances in ear reconstruction with autogenous rib cartilage grafts: personal experience with 1200 cases. *Plast Reconstr Surg* 104: 319-334, 1999
- 2) Koshima I , Umeda N, Moriguchi T, Handa T, Akisada K, Orita Y :A full-thickness chondrocutaneous flap from the auricular choncha for repair of tracheal defects. *Plast Reconstr Surg* 99:1887-1893, 1997
- 3) Martinez JM, Alconchel MD, Olivares C, Cimorra GA :Reconstruction of the tragus after tumor excision. *Brit J Plast Surg* 50 :552-554, 1997
- 4) Nagata S:Modification of the stages in total reconstruction of the auricle: Part I : Grafting the three dimensional costal cartilage framework for lobule type microtia. *Plast Reconstr Surg* 93: 221-230, 1994
- 5) Ono I, Ohura T, Kimura C, Murazumi M, Sakamura R, Misawa HTA :Correction of microtia with construction of the tragus using a chondrocutaneous flap. *Brit J Plast Surg* 44:250-258, 1991
- 6) Park C,Lineaweaver WC,Rumly TO,Buncke HJ :Arterial supply of the anterior ear. *Plast Reconstr Surg* 90:38-44, 1992
- 7) Parkhouse N and Evans D :Reconstruction of the nose using a composite free flap from the pinna. *Brit J Plast Surg* 38:306-313, 1985
- 8) Symmonds FC, Crikelair GF :Auricular composite grafts in nasal reconstruction: A report of 36 cases. *Plast Reconstr Surg* 37:433-437, 1966
- 9) Tanaka Y,Tajima S,Tsujiguchi K, et al. :Microvascular reconstruction of nose and ear defects using composite auricular free flaps. *Ann Plast Surg* 31:298-302, 1993
- 10) Yotsuyanagi T, Urushidate S, Nihei Y, Yokoi K, Sawada Y :Reconstruction of congenital stenosis of external auditory canal with a postauricular chondrocutaneous flap. *Plast Reconstr Surg* 102:2320-2324, 1998