

A case report of measles in a premature infant and the antibody and/or the virus RNA in the patients contracted in infancy

Mika INOUE, Kihei TERADA, Tokio WAKABAYASHI
Satoko OGITA, Kouzou KAWASAKI, Kazunobu OUCHI

Department of Pediatrics, Kawasaki Medical School, 577 Matsushima, Kurashiki, 701-0192, Japan

ABSTRACT We treated a two-month-old infant, delivered prematurely at 32 weeks of gestational age who contracted measles from his mother. We checked him regularly for ten years because of the risk of developing subacute sclerosing panencephalitis (SSPE). As a result he has been healthy, but his measles specific IgG antibody titer became negative after five years and was subsequently boosted with a vaccination. Thus, we determined the IgG and IgM antibodies with an ELISA kit in the participating 11 healthy children, who were diagnosed as having measles under one year old at our hospital between 2000 and 2006. Two boys had an IgG antibody titer of above the upper detection limit, but no participants were negative. The measles RNA was not detected with the loop-mediated isothermal amplification in plasma and peripheral blood mononuclear cells in the two patients. There have been some reports of an early onset and rapidly progressive SSPE after perinatal measles. We infer that specific immunity disappearance after infection at an early age due to immature immunity may be associated with activating the measles virus remaining in the brain.

(Accepted on June 20, 2011)

Key words : Measles, SSPE, Antibody, Infancy, Immunity

INTRODUCTION

Subacute sclerosing panencephalitis (SSPE) is a slow, progressive degenerative disease of the central nervous system caused by a persistent measles virus infection. Most patients with SSPE have a history of primary measles infection at an early age, which is followed by the onset of the progressive neurological disorder in a latent period of 6-8 years¹⁾. Typically, the neurologic dysfunction begins with behavioral difficulties that progress to myoclonic activity and

eventually into complete neurologic deterioration¹⁾. The pathogenesis of the disease is controversial and considered to be either a defective production of the matrix protein^{2,3)} or fusion protein⁴⁾ by infected cells and an irregular antigenic modulation by antibodies, or a disruption of cytokine synthesis, alteration of apoptosis and negative signaling of T cells by the viral glycoprotein⁵⁾.

In Japan measles epidemics are decreasing, but there were epidemics from 2000 to 2001 and from

Corresponding author
Kihei Terada
Department of Pediatrics, Kawasaki Medical School,
577 Matsushima, Kurashiki, 701-0192 Japan

Phone : 81 86 462 1111
Fax : 81 86 462 1199
E-mail : m.inoue@med.kawasaki-m.ac.jp
kihei@med.kawasaki-m.ac.jp

2007 to 2008. We believe that measles still remains endemic in Japan; there were approximately 11,000 measles patients reported in 2008. A second immunization was introduced in 2006 in order to eliminate this disease by 2012. The inoculation rate among one-year-old children reached 94.3% in 2008. The reported cases of measles decreased to 736 (5.8/million population) in 2009.

CASE REPORT

A two-month-old boy was referred to our hospital because his mother was diagnosed as having measles. The patient, who was 2,062g at birth, was delivered at 32 weeks of gestational age by an urgent Caesarean section because of a hemorrhage in the lower placenta. The boy was treated for respiratory distress syndrome by bronchial administration of surfactant and with a respirator for seven days. On the referral day, there were no symptoms or signs, but he was administered 2.0 mL of immunoglobulin intramuscularly to prevent

the measles. However, the next day, the patient was admitted to our hospital because of the appearance of reddish exanthema and a reduced milk volume intake. A physical examination revealed reddish maculopapular exanthema mainly on the trunk, but Koplik spots were not observed in the oral cavity. His father was also admitted to our hospital because of measles. A diagnosis of measles in his parents was then confirmed by the IgM antibodies and significant increases of IgG antibodies. The patient's white blood cell count (WBC) was $14,500/\text{mm}^3$ with 2% neutrophil bands, 15% segmented neutrophils, 2% eosinophils, 1% basophils, 12% monocytes, 59% lymphocytes and 9% atypical lymphocytes. The measles specific IgM antibody was positive. After his admission, his exanthema spread from the trunk to the rest of the body, but his temperature remained below 38.0 C and no remarkable cough or rhinorrhea developed. We discussed the risk of subacute sclerosing panencephalitis (SSPE) in the future with his parents, and then obtained their

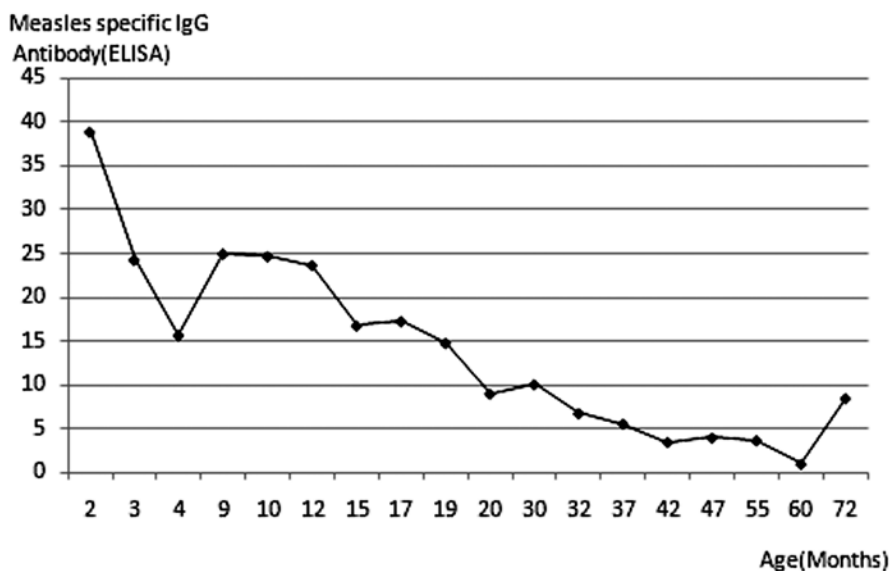


Figure. Alteration of IgG antibodies against measles

The IgG antibodies titers are expressed as ELISA units. The negative and positive cutoff of the IgG value is <2.0 and ≥ 4.0 , respectively. The administered IgG antibody decreased gradually and thereafter the IgG antibody titers increased. However, the IgG antibody titer became negative, and was then boosted with the vaccination.

informed consent to draw cerebrospinal fluid from him for a laboratory examination and to monitor his development and antibody titer. On the sixth day after admission, his cerebrospinal fluid was taken to detect the measles virus by culture and RT-PCR⁶⁾. Both results were negative.

The boy's IgM antibody titer, which was 15.2 at the onset, decreased to 6.3 after four weeks and was 1.1 at eight weeks after the onset. The changes in the measles specific IgG antibody are shown in the Figure. The IgM and IgG antibodies titers are expressed as ELISA units. The positive cutoff values were ≥ 1.2 and ≥ 4.0 , IgM and IgG, respectively. His IgG antibody titers decreased to 24.3 after four weeks and was 15.7 at eight weeks after the onset, but then increased to 25.0 five months later. The IgG antibody titers became negative after four years, ten months. Furthermore, the virus RNA was not detected in his plasma and PBMC with RT-PCR. He was immunized with a combined measles and rubella vaccine, after which his IgG antibody increased to 8.5, positive. The IgM antibody, however, remained negative.

SUBJECTS AND METHODS

The subjects who were diagnosed as having measles in infancy under one year old were enlisted for this research conducted at Kawasaki Medical

School Hospital between 2000 and 2006 based on clinical features and/or the existence of a positive IgM antibody. The collection and use of human materials for the present study were approved by the Kawasaki Medical School Ethics Committee on Human Subjects. Blood were drawn to determine the antibodies after informed consents were obtained from their guardians. This was done to detect SSPE risk in the subjects. We then measured the measles RNA using the loop-mediated isothermal amplification (LAMP) method⁷⁾ in the plasma and peripheral blood mononuclear cells (PBMC) of the subjects who were thought to be at risk of developing SSPE.

RESULTS

Eleven children were enlisted from the fifteen patients diagnosed as having measles under one year old. They were from two to four years of age and nine (60%) were male. The measles specific IgM and IgG antibodies were measured in the serum with the ELISA assay (Denka Seiken Co., Japan) according to the manufacturer's instructions. The characteristics and results are shown in the Table. Two boys had IgG antibody titers above the upper detection limit of 128, but no one had a negative titer. We asked their guardians about the possibility of exposure to measles patients in hospitals or

Table. Characteristics and results of the participating children diagnosed as having measles under one year old.

N	Age of infection (months)	Age at collecting samples	Measles specific IgM (ELISA)	Measles specific IgG (ELISA)	Measles vaccination
1	11	7Y11M	0.32	62	non
2	8	7Y7M	0.29	12.3	non
3	7	7Y4M	0.53	49.7	non
4	7	7Y4M	0.62	>128	non
5	8	7Y4M	0.51	16.4	1 dose
6	4	7Y3M	0.47	52.7	non
7	11	5Y9M	0.52	13.9	1 dose
8	9	8Y2M	0.34	19.6	non
9	10	8Y3M	non	21.7	1 dose
10	10	2Y5M	0.48	>128	non
11	5	11M	0.36	55.1	non

kindergartens, but they were unaware of any recent exposure. The measles virus RNA was not detected in plasma and PBMC in the two subjects who had the titers above the maximum.

DISCUSSION

Most patients with SSPE have a history of primary measles infection at an early age. Children infected with measles under the age of one year carry a risk 16 times greater than those infected at age five year or later⁸⁾. A higher incidence (male/female ratio 3:1) has also been noted in boys⁹⁾. The two-month-old male patient was delivered at 32 weeks of gestational age and contracted measles from his mother. If he was born at full term his infection would have been classified as perinatal measles. SSPE is followed by the onset of a progressive neurological disorder in a latent period of 6-8 years. However, there have been some reports of a very early onset and rapid, progressive SSPE after a perinatal measles infection, that is, the congenital¹⁰⁻¹³⁾ or neonatal infection¹⁴⁾. These observations suggest that immature immunity during the intrauterine or neonatal period is associated with the failure to inhibit a persistent infection in the brain. However, there have been few reports on immunological observations of infant hosts.

The patient and his parents were confirmed as having measles through the specific IgM antibody against measles. His mother had no past history of infection or vaccination. Although we administered gammaglobulin to him, the onset of an eruption occurred the next day. We thought that the administration of gammaglobulin was too late to influence his clinical course. However, his measles infection was mild. With the presence of the transplacental antibodies against measles, the clinical course of measles is thought to be usually mild. But, in a situation without these antibodies such as congenital measles we thought this morbidity would be severe. However, the clinical

courses of neonate cases found in the literatures have been described as being mild¹⁰⁻¹⁴⁾. Chiba *et al.*¹⁵⁾ described that the extremely low morbidity of recent congenital measles make it difficult to evaluate the efficacy of prophylactic immunoglobulin injections to infants with a suspicious congenital measles infection. The mild morbidity may be related to a low immune response such as cytokines. We followed up on the patient regularly for ten years and as a result he has been healthy. In this case, the IgG antibody titers decreased gradually within the first four months, which we administered as gammaglobulin. Following this the IgG antibody titers increased, which were produced by him naturally. The IgG antibody titer became negative 58 months after the onset and was then boosted with a vaccination.

Because perinatal measles infection is very rare, instead of researching it we decided to investigate measles cases in patients under one year old, who have a risk factor of SSPE. Among the participating 11 healthy children, the IgG antibody titers were above the upper detection limit in two boys. However, they have had no recent history of exposure to friends with measles or been in cities with epidemics. Therefore, we suspected some possibility of pre-stage SSPE in them and expected to find the virus RNA, but it was not detected using the LAMP method. There has not been any onset of SSPE among them, although a few years have already passed. Ragazzi *et al.*¹⁶⁾ reported that the virus RNA persisted in PBMC for 157 days after birth in congenital measles.

In conclusion, we inferred that the disappearance of specific immunity after infection at an early age may be one of the pathogenesis of SSPE. However, we could not find any patients without the specific IgG antibody or detect the virus RNA in the 11 children who contracted natural measles under one year old. However, we believe that further research of the kind in this article will be required to clarify

the relation of immature immunity and SSPE.

REFERENCES

- 1) Garg RK: Subacute sclerosing panencephalitis. *Postgrad Med J* 78:63-70, 2002
- 2) Carter MJ, Willcocks MM, ter Meulen V: Defective translation of measles virus matrix protein in a subacute sclerosing panencephalitis cell line. *Nature* 305:153-155, 1983
- 3) Cathomen T, Mrkic B, Spehner D, Drillien R, Naef R, Pavlovic J, Aguzzi A, Billeter MA, Cattaneo R: A matrix-less measles virus is infectious and elicits extensive cell fusion: consequences for propagation in the brain. *EMBO J* 17:3899-3908, 1998
- 4) Watanabe M, Wang A, Sheng J, Gombart AF, Ayata M, Ueda S, Hirano A, Wong TC: Delayed activation of altered fusion glycoprotein in a chronic measles virus variant that causes subacute sclerosing panencephalitis. *J Neurovirol* 1:177-188, 1995
- 5) Schneider Schaulies S, ter Meulen V: Pathogenic aspects of measles virus infections. *Arch Virol suppl* 15:139-158, 1999
- 6) Nakayama T, Mori T, Yamaguchi S, Sonoda S, Asanuma S, Yamashita R, Takeuchi Y, Urano T: Detection of measles virus genome directly from clinical samples by reverse transcriptase-polymerase chain reaction and genetic variability. *Virus Res* 35:1-16, 1995
- 7) Fujino M, Yoshida N, Yamaguchi S, Hosaka N, Ota Y, Notomi T, Nakayama T: A simple method for the detection of measles virus genome by loop-mediated isothermal amplification (LAMP). *J Med Virol* 76:406-413, 2005
- 8) Miller C, Farrington CP, Harbert K: The epidemiology of subacute sclerosing panencephalitis in England and Wales 1970-1989. *Int J Epidemiol* 21:998-1006, 1992
- 9) Halsey NA, Modlin JF, Jabbour JT, Dubey L, Eddins DL, Ludwig DD: Risk factors in subacute sclerosing panencephalitis: a case control study. *Am J Epidemiol* 111:415-424, 1980
- 10) Zwiauer K, Forstenpointner E, Popow-Kraupp T, Hauser E, Jellinger KA: Rapid progressive subacute sclerosing panencephalitis after perinatally acquired measles virus infection. *Lancet* 345:1124, 1995
- 11) Cruzado D, Masserey-Spicher V, Roux L, Delavelle J, Picard F, Haenggeli CA: Early onset and rapidly progressive subacute sclerosing panencephalitis after congenital measles infection. *Eur J Pediatr* 161:438-441, 2002
- 12) Dasopoulou M, Covanis A: Subacute sclerosing panencephalitis after intrauterine infection. *Acta Paediatr* 93:1251-1253, 2004
- 13) Ohji G, Satoh H, Satoh H, Mizutani K, Iwata K, Tanaka-Taya K: Congenital measles caused by transplacental infection. *Pediatr Infect Dis J* 28:166-167, 2009
- 14) Sawaishi Y, Abe T, Yano T, Ishikawa K, Takada G: SSPE following neonatal measles infection. *Pediatr Neurol* 20:63-65, 1999
- 15) Chiba ME, Saito M, Suzuki N, Honda Y, Yaegashi N: Measles infection in pregnancy. *J Infect* 47 :40-44, 2003
- 16) Ragazzi SLB, Vaz-de-lima LRA, Bellini WJ, Gilio AE, Vaz FAC, Durigon EL: Congenital and neonatal measles during an epidemic in Sao Paulo, Brazil in 1997. *Pediatr Infect Dis J* 24 :377-378, 2005