

〈Case Report〉

A case of fulminant amebic colitis that could be saved

Daisuke UENO, Haruaki MURAKAMI, Yuko OKAMOTO, Akimasa KAWAI,
Hisako KUBOTA, Masaharu HIGASHIDA, Yasuo OKA, Toshimasa OKADA,
Atsushi TSURUTA, Hideo MATSUMOTO, Tomio UENO

Department of Digestive Surgery, Kawasaki Medical School

ABSTRACT An 80-year-old man was admitted to a neighboring hospital with severe diarrhea and bloody stools. He did not have a remarkable medical history, was not homosexual, and had not traveled outside the country for several years. Colonoscopy was performed on the day of admission and revealed multiple ulcerations with edematous mucosa throughout the colorectum. Histopathological findings of biopsy specimen could not identify the reason for the inflamed colon. On postadmission day 6, the patient developed severe abdominal pain and underwent an emergent surgery for pan-peritonitis due to bowel perforation. The laparotomy revealed glossy fecal pan-peritonitis with perforation of the sigmoid colon; necrosis was observed through the entire length of the colon. The colonic tissue was extremely fragile and exhibited a blotting paper-like appearance. Total colectomy, sigmoid mucous fistula, ileostomy, and intraperitoneal drainage were performed. On postadmission day 12, histopathological findings of resected specimen raised the suspicion of amebic dysentery, and we accordingly treated him with metronidazole (2,250 mg/day) administered orally. Abdominal CT images taken on days 12 and 20 postadmission showed multiple liver abscesses, which improved following metronidazole administration. Metronidazole was discontinued 14 days after initiation as the patient's general condition improved. His condition remained stable thereafter, and he was transferred two months after admission.

doi:10.11482/KMJ-E43(1)13 (Accepted on February 23, 2017)

Key words : Fulminant amebic colitis, Metronidazole

INTRODUCTION

Amebic colitis is caused by the protozoan parasite *Entamoeba histolytica*. Cases of fulminant amebic colitis are rare, and among them, non-fatal cases are rarer due to the associated high mortality rate. The disease results in intestinal tract perforation and peritonitis, which, when chronic, result in

poor prognosis. We saved a patient with fulminant amebic colitis that resulted in necrosis of the entire colorectum and report here its successful diagnosis and management.

CASE REPORT

An 80-year-old man was admitted to hospital with

Corresponding author
Daisuke Ueno
Department of Digestive Surgery, Kawasaki Medical
School, 577 Matsushima, Kurashiki, 701-0192, Japan

Phone : 81 86 462 1111
Fax : 81 86 462 1199
E-mail: daisuke0111@hotmail.co.jp

severe diarrhea and bloody stools. He did not have a remarkable medical history, was not homosexual, and had not traveled outside the country for several years. Physical examination revealed a slightly distended abdomen, but no palpable masses. Preoperative laboratory data revealed leukocytosis, hypoproteinemia, hyperglycemia, elevated

C-reactive protein and procalcitonin levels, and an electrolyte imbalance (Table 1). Colonoscopy was performed on the day of admission and revealed multiple ulcerations with edematous mucosa throughout the colorectum (Fig. 1). The biopsy sample was collected from a site near the rectal inflammation. Histopathological findings of biopsy

Table 1. Laboratory examination results on admission

WBC	11,330 / μ L	TP	4.0 g/dL	Na	132 mEq/L
Neut	79 %	Glu	132 mg/dL	K	2.6 mEq/L
Mono	4 %	T-Bil	0.5 mg/dL	Cl	98 mEq/L
Eos	0 %	ALP	276 IU/L		
Lym	16 %	T-cho	94 mg/dL	CMV C7-HRP	(-)
A-Ly	1 %	γ -GTP	47 IU/L	Anti-O157 LPS antibody	(-)
RBC	461×10^4 / μ L	LDH	260 IU/L	EB-VCA IgG	(+)
Hb	13.3 g/dL	Alb	1.4 g/dL	EB-VCA IgM	(-)
Ht	38.7 %	Glb	2.6 g/dL	EB-EA IgG	(\pm)
Plt	33.4×10^4 / μ L	ChE	27 IU/L	EB-EBNA IgG	(+)
		AST	24 IU/L	Procalcitonin	1.04 ng/mL
		ALT	27 IU/L	Anti-HIV antibody	(-)
		Cr	0.69 mg/L		
		BUN	10 mg/dL		
		CRP	21.67 mg/dL		

WBC, white blood cell; Neut, neutrophil; Mono, monocyte; Eos, eosinophil; Lym, lymphocyte; RBC, red blood cells; Hb, hemoglobin; Ht, hematocrit; Plt, platelet; TP, Total protein; Glu, glucose; T-Bil, total bilirubin; ALP, alkaline phosphatase; T-cho, total cholesterol; γ -GTP, gamma glutamyl transpeptidase; LDH, lactate dehydrogenase; Alb, albumin; Glb, globulin; ChE, cholinesterase; AST, aspartate aminotransferase; ALT, alanine aminotransferase; Cr, creatinine; BUN, blood urea nitrogen; CRP, C-reactive protein; Na, sodium; K, potassium; Cl, chloride; CMV, cytomegalovirus; HRP, horseradish peroxidase; O157, *E. coli* serotype O157; LPS, lipopolysaccharide; EB, Epstein-Barr virus; VCA, viral capsid antigen; IgG, immunoglobulin G; EA, envelope antigen; EBNA, Epstein-Barr nuclear antigen; HIV, human immunodeficiency virus; +, positive test result; -, negative test result; \pm , equivocal test result.

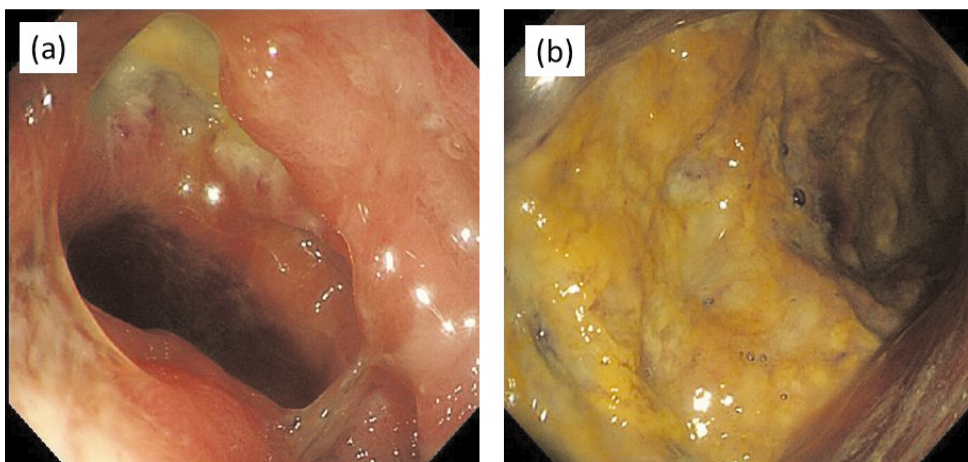


Fig. 1 Colonoscopy on admission

- (a) Rectum: multiple ulcerations with edematous mucosa,
 (b) Sigmoid colon: yellowish white coating on a colic mucous membrane.

specimen could not identify the reason for the inflamed colon. From postadmission day 2 to 5, he was fasting, and meropenem (0.5 g every 12 hours) was prescribed. On postadmission day 6, the patient developed severe abdominal pain and underwent an emergent surgery for pan-peritonitis due to bowel perforation. An enhanced computed tomography (CT) showed prominent edema and thickening of the entire colorectum (Fig. 2). Other than a few ascites and free air, no obvious pathologies were observed in the other organs. The laparotomy revealed

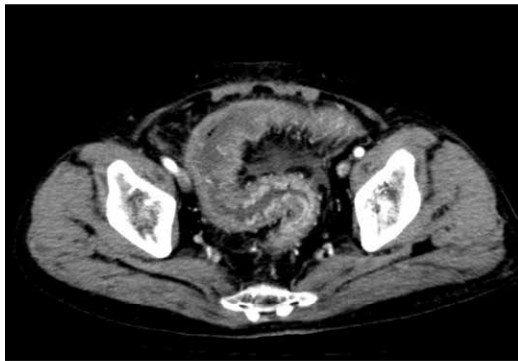


Fig. 2 Abdominal enhanced computed tomography performed on day 6 postadmission: prominent edema and thickening of the entire colorectum.

glossy fecal pan-peritonitis with perforation of the sigmoid colon; necrosis was observed through the whole wall of the colon. The colonic tissue was extremely fragile and exhibited a blotting paper-like appearance (Fig. 3). Total colectomy, sigmoid mucous fistula, ileostomy, and intraperitoneal drainage were performed. On postadmission day 12, histopathological findings of resected specimen had been revealed amebic dysentery (Fig. 4). An anti-*Entamoeba histolytica* (EH) antibody test returned positive results. However, the patient's family members tested negative for the anti-EH antibodies. We accordingly treated him with metronidazole (2,250 mg/day) administered orally. The patient's condition improved gradually following the surgery and metronidazole administration. Abdominal CT images taken on days 12 and 20 postadmission showed multiple liver abscesses (Fig. 5), which improved following metronidazole treatment. Metronidazole was discontinued 14 days after initiation as the patient's general condition improved. His condition remained stable thereafter, and he was transferred two months after admission. It was indicated transition of the inflammatory

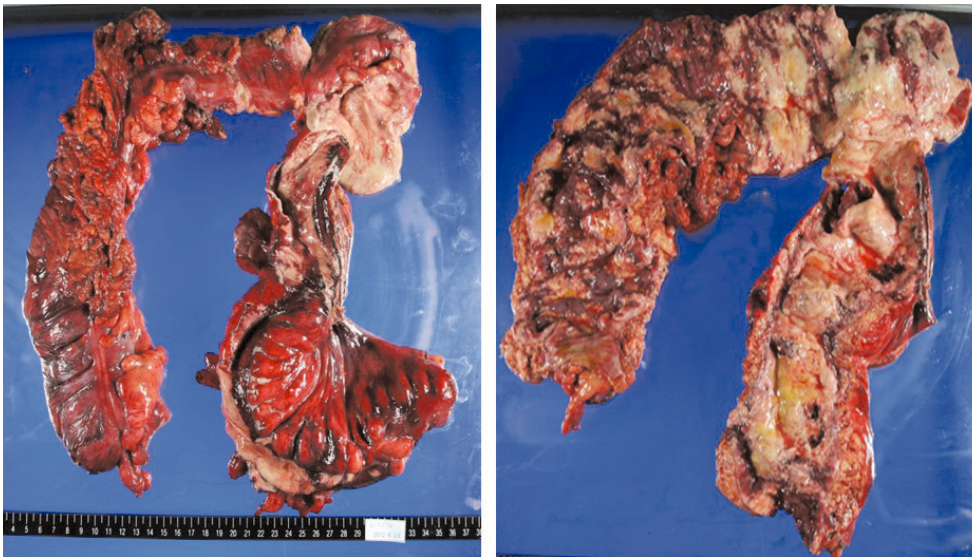


Fig. 3 Macroscopic findings: extremely fragile colorectal tissue with a blotting paper-like appearance. Mucosal surface has necrosis, ulceration, and severe inflammatory findings up to the serosal surface.

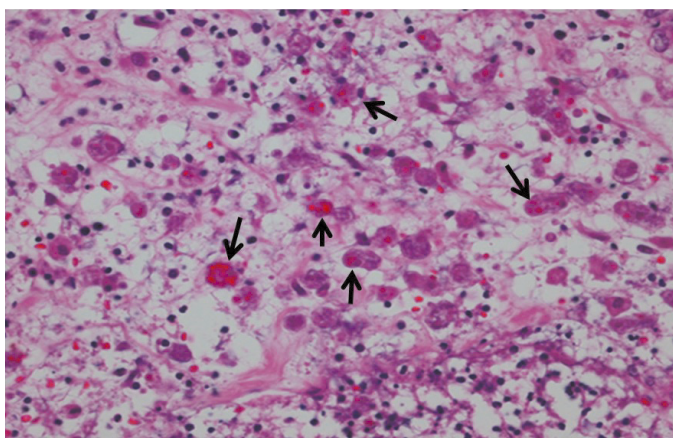


Fig. 4 Histopathological findings: amebic colitis was noted in the histopathology. It showed ameba bugs (arrow).

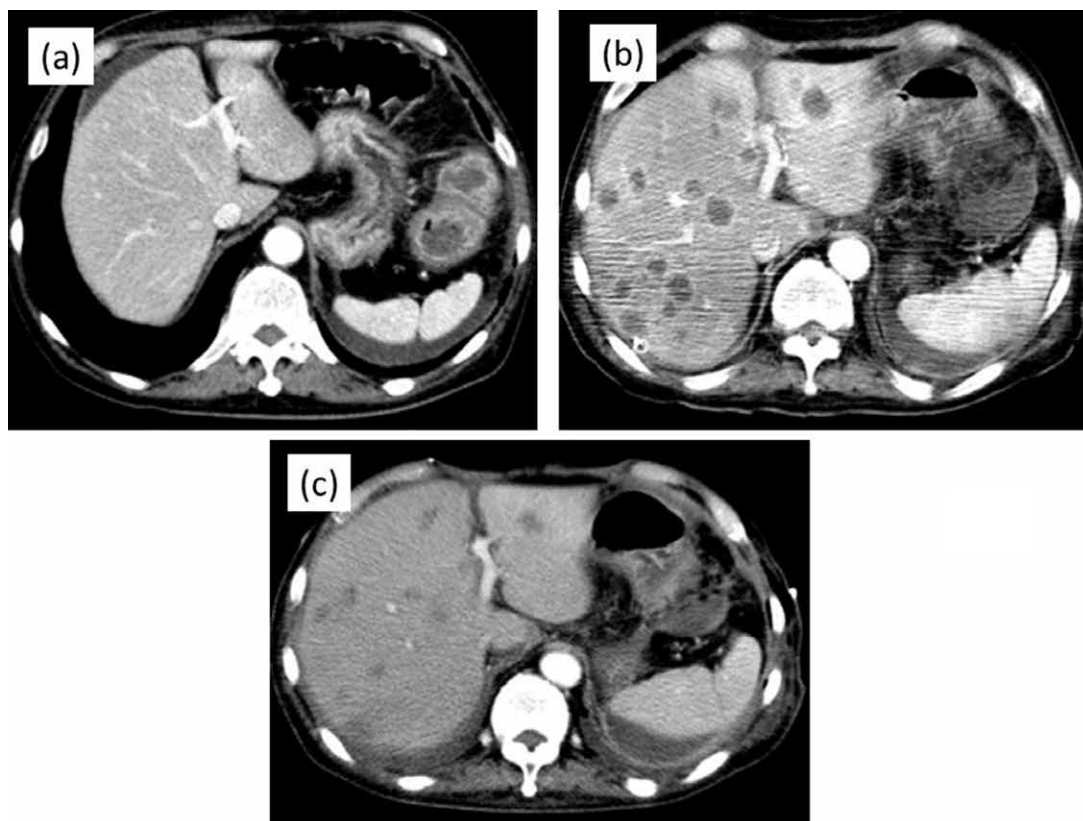


Fig. 5 Abdominal enhanced computed tomography
(a) On hospital day 6: no liver abscess;
(b) on hospital day 12: the presence of multiple liver abscesses;
(c) on hospital day 20 (following metronidazole administration): improvement noted for the multiple liver abscesses.

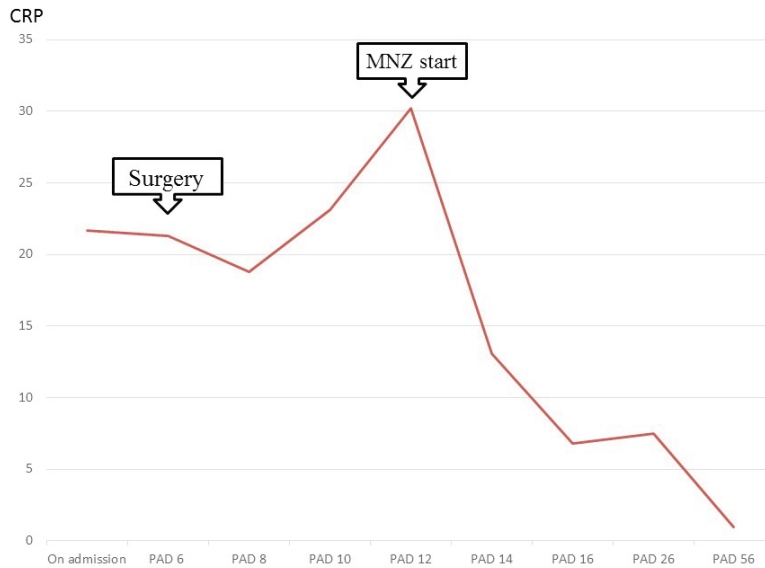


Fig. 6 Transition of the inflammatory response after admission
CRP c-reactive protein, MNZ metronidazole, PAD postadmission day

response after admission (Fig. 6).

DISCUSSION

Amebic colitis is an infectious disease that develops due to oral ingestion of *E. histolytica* through contaminated food or water¹⁾. The active disease develops in approximately 10% of the infected patients, while the remaining are asymptomatic cyst carriers²⁾. Most cases of amebic colitis are chronic, with repeated relapses of diarrhea, bloody stool, abdominal distention, and abdominal pain followed by periods of remission. Acute infection exhibits bacillary dysentery-like symptoms including bloody stool and abdominal pain and is called amebic colitis. Patients with fulminant amebic colitis develop intestinal tract perforation, and multiple organ failures due to widespread, rapidly progressive necrosis of the large intestine, that results in a high rate of mortality. The frequency of fulminant cases is approximately 3%³⁾, and presents with fever due to the ongoing necrosis and peritonitis, abdominal pain, altered consciousness,

and toxic megacolon. The mortality rate of fulminant cases is 55-100%, the prognosis is extremely poor. Patients with amebic colitis typically present with a several-week history of cramping abdominal pain, weight loss, and watery or bloody diarrhea⁴⁾. The amebic infection is often sexually transmitted or associated with developing countries travel⁵⁾. Among men who have sex with men (MSM), the prevalence of *E. histolytica* infections is higher due to multiple sexual partners. The sexual transmission of amebiasis is most commonly seen in MSM⁶⁾. However, the high rates of *E. histolytica* infections in homosexual men previously reported in the United States actually reflect a high prevalence of *E. dispar* infection in this population⁴⁾. In contrast, in Asia, amebiasis is more frequently a symptom of human immunodeficiency virus (HIV) infection and acquired immunodeficiency syndrome (AIDS); through the sexual practices of MSM, the risk of acquiring HIV is similar to that of amebiasis^{7, 8)}. Even though the cause of development of fulminant amebic colitis is unclear, it occurs more frequently

in the immunocompromised state such as in the case of the elderly (>60 years), chronic alcoholism, malignant tumor merger, steroid use, and pregnancy, all of which affect host immunity⁹⁻¹¹⁾. In this case, the patient was not homosexual, did not have a history of recent foreign travel, and was not currently sexually active. We thus speculated oral transmission in this case as the cause of amebic infection; however, because anti-EH antibodies were not detected in family members who lived with the patient, we could not identify the route of infection. In addition, the fulminant cause happened to be associated with compromised host immunity, as the patient was elderly.

The preoperative diagnosis of fulminant amebic colitis is often difficult, and its differentiation from inflammatory bowel disease and other infectious enteritis is necessary. Norio *et al.*¹²⁾ reported a 12% rate of preoperative amoebic colitis diagnosis. In addition, they reported a mortality rate of 28.6% among seven amoebic colitis cases where a preoperative diagnosis was possible, whereas the mortality rate was 78.4% for 51 cases where a preoperative diagnosis was not made, highlighting the importance of early diagnosis and initiation of appropriate treatment¹²⁾. The preoperative disease diagnosis rate is low and is usually based on an initial histopathological examination of an excised biopsy specimen, which is collected frequently in such cases. Serological examinations return positive results in less than 88% of the patients with amoebic dysentery¹³⁾. Definitive diagnosis is usually based on an examination of colon biopsy samples. A high index of clinical suspicion should be maintained in cases of unidentified severe enteritis, and appropriate diagnostic methods should be chosen accordingly. We were unable to reach a preoperative diagnosis in this case; however, we believe that a favorable outcome was made possible by correctly diagnosing fulminant amoebic colitis following an emergent surgery. In addition, we also thought intensive care

that prevent to multiple organ failure would lead good outcome. When the disease is suspected based on endoscopic findings, a serum anti-EH antibody test should be performed immediately and may help to avoid emergent surgery.

CONCLUSION

We experienced a case of fulminant amebic colitis that we were able manage successfully through emergent surgery and metronidazole administration. The disease should be suspected in cases where an endoscopic examination reveals yellowish white coating on the colic mucous membrane. By performing appropriate biopsy sampling and examinations, and detecting serum anti-EH antibodies early in the disease course, we could reach the correct diagnosis and were able to successfully manage the case.

REFERENCES

- 1) Salit IE, Khairnar K, Gough K, Pillai DR: A possible cluster of sexually transmitted *Entamoeba histolytica*: genetic analysis of a highly virulent strain. *Clin Infect Dis* 49: 346-353, 2009
- 2) Reed SL: Amebiasis: An update. *Clin Infect Dis* 14: 385-393, 1992
- 3) Adams EB, MacLeod IN: Invasive amebiasis. I. Amebic dysentery and its complications. *Medicine* 56: 315-323. 1977
- 4) Haque R, Huston CD, Hughes M, Houpt E, Petri WA Jr: Amebiasis. *N Engl J Med* 348: 1565-1573. 2003
- 5) Yoshikawa I, Murata I, Yano K, Kume K, Otsuki M: Asymptomatic amebic colitis in a homosexual man. *Am J Gastroenterol* 99: 2306-2308, 1999
- 6) Moran P, Ramos F, Ramiro M, Curiel O, González E, Valadez A, Gómez A, García G, Melendro EI, Ximénez C: *Entamoeba histolytica* and/or *Entamoeba dispar*: infection frequency in HIV+/AIDS patients in Mexico City. *Exp Parasitol* 110: 331-334, 2005
- 7) Hsu MS, Hsieh SM, Chen MY, Hung CC, Chang SC: Association between amebic liver abscess and human immunodeficiency virus infection in Taiwanese subjects. *BMC Infect Dis* 8: 48, 2008

- 8) Hung CC, Deng HY, Hsiao WH, Hsieh SM, Hsiao CF, Chen MY, Chang SC, Su KE: Invasive amebiasis as an emerging parasitic disease in patients with human immunodeficiency virus type 1 infection in Taiwan. *Arch Intern Med* 165: 409-415, 2005
- 9) Chauh SK, Sheen IS, Changchien CS, Chiu KW, Fan KD: Risk factors associated with fulminant amebic colitis. *J Formos Med Assoc* 95: 446-451, 1996
- 10) Takahashi T, Gamboa-Dominguez A, Gomez-Mendez TJ, Remes JM, Rembis V, Martinez-Gonzalez D, Gutierrez-Saldivar J, Morales JC, Granados J, Sierra-Madero J: Fulminant amebic colitis: analysis of 55 cases. *Dis Colon Rectum* 40: 1362-1367, 1997
- 11) Stanley SL Jr: Amoebiasis. *Lancet* 361: 1025-1034, 2003
- 12) Yukawa N, Nagano A, Fujisawa J, Matsukawa H, Shimizu S, Tomita Y: A case of fulminating amoebic colitis associated with colon perforation. *J Jpn Surg Assoc* 64: 2211-2216, 2003
- 13) Kagan IG: Serologic diagnosis of parasitic diseases. *N Engl J Med* 282: 685-686, 1970

