

〈Review〉

## Application of modified shrinking field radiation in RT-DeVIC chemoradiotherapy for treating localized extranodal natural killer/T-cell lymphoma

Ryouji TOKIYA<sup>1)</sup>, Eisaku YODEN<sup>1)</sup>, Yoshiko MATSUHASHI<sup>2)</sup>,  
Nobuhiko KAMITANI<sup>1)</sup>, Yujiro KAWATA<sup>1)</sup>, Fuminori SANO<sup>2)</sup>,  
Hirotake NISHIMURA<sup>3)</sup>, Hirotoshi TOKUNAGA<sup>2)</sup>, Toshinori KONDO<sup>2)</sup>,  
Hideho WADA<sup>2)</sup>, Takashi SUGIHARA<sup>2)</sup>, Junichi HIRATSUKA<sup>1)</sup>

*1) Department of Radiation Oncology, Kawasaki Medical School,*

*2) Department of Hematology, Kawasaki Medical School,*

*3) Department of Pathology, Kawasaki Medical School*

**ABSTRACT** Concurrent chemoradiotherapy (CRT) is the recommended treatment for localized extranodal natural killer/T-cell lymphoma, nasal type (ENKL). In 2009, the Japan Clinical Oncology Group first documented the safety and efficacy of a regimen involving radiotherapy (RT) plus dexamethasone, etoposide, ifosfamide, and carboplatin (DeVIC) in their phase I/II trials (JCOG0211 study). The application of this regimen has drastically improved outcomes of patients with localized ENKL. In 2013, the current guidelines were made to the cost in JCOG0211 study.

We retrospectively investigated the outcomes of three patients who received CRT for stage localized ENKL at the Kawasaki Medical School Hospital between August 2007 and March 2011. Our CRT protocol differed from that used in the JCOG0211 study as we used a different shrinking field RT method. A recent report on shrinking or extended-field RT raised questions regarding which fields are appropriate. Thus, we compared our clinical results with those of the JCOG0211 study and analyzed the effect of the differences in field size on clinical results. The median follow-up of the three patients in the present study was 9 months (range, 5-106 months), two and one of whom achieved complete and partial responses, respectively. Regarding adverse events, no severe acute side effects (e.g., mucositis) higher than Grade 4 were observed.

We reviewed cases and the JCOG0211 study which we experienced in the past about fields of the RT. The present study described our experiences with three patients receiving shrinking field RT.

doi:10.11482/KMJ-E202046017 (Accepted on December 25, 2019)

Key words : Extranodal natural killer/T-cell lymphoma, nasal type, shrinking field radiotherapy, JCOG0211 study

---

Corresponding author

Ryouji Tokiya

Department of Radiation Oncology, Kawasaki Medical  
School, 577 Matsushima, Kurashiki, 701-0192, Japan

Phone : 81 86 462 1111

Fax : 81 86 462 1199

E-mail: tokiya@med.kawasaki-m.ac.jp

## INTRODUCTION

Localized extranodal natural killer/T-cell lymphoma, nasal type (ENKL) is a rare type of lymphoma with a relatively high prevalence in East Asia<sup>1-3)</sup>. Based on the results of studies conducted in the 1990s<sup>3)</sup>, approximately 70–90% of ENKL cases involved localized disease<sup>4)</sup> with a poor response to cyclophosphamide, doxorubicin, vincristine, and prednisone chemotherapy. Although the transient remission of localized ENKL has been observed, with a complete response (CR) rate of 65%, the rate of recurrence is high with radiotherapy (RT) alone; consequently, poor prognosis is observed for long-term survival<sup>5)</sup>. More recently, concurrent chemoradiotherapy (CRT) based on a dexamethasone, etoposide, ifosfamide, and carboplatin regimen (a two-third dose of DeVIC [2/3DeVIC]) has been recommended for treating localized ENKL in Japan, which has increased the 5-year overall survival rate by 70%<sup>6, 7)</sup>. The Japan Clinical Oncology Group (JCOG) 0211 study by Yamaguchi *et al.*<sup>6-8)</sup> was the first to evaluate the clinical response of concurrent CRT using DeVIC. In 2013, RT plus 2/3DeVIC therapy became the standard treatment for localized ENKL in Japan. However, a recent report of shrinking field<sup>9-14)</sup> or extended-field<sup>6, 7, 14)</sup> RT has raised debate regarding which fields are appropriate.

The Kawasaki Medical School Hospital uses treatment protocols that differ in chemotherapy and RT fields from those described in the JCOG0211 study. This study retrospectively compared the clinical outcomes of patients who received CRT for localized ENKL at our hospital before the introduction of RT plus 2/3DeVIC therapy with those of patients who participated in the JCOG0211 study to analyze the effects of the differences in radiation field size on clinical results. This study assessed the efficiency of full-DeVIC combined with shrinking field RT in treating localized ENKL.

### *Modified radiation fields in RT for treating ENKL*

The extent of the clinical target volume (CTV) and the optimal dose in RT remain controversial for patients with localized ENKL<sup>9)</sup>. Several studies defined an extended CTV encompassing the entire nasal cavity, nasopharynx, bilateral paranasal cavity, and gross tumor volume (GTV)<sup>6, 7, 15)</sup>, while others defined a smaller target volume<sup>9-14)</sup>. Recent novel chemoradiotherapy regimens have achieved 2-year overall survival (OS) rates of 76-89%<sup>6, 7, 10, 15-17)</sup>; therefore, concerns regarding late radiation toxicities and the quality of survivorship are increasing. Because localized ENKL is generally located in the nasal cavity, the exposure of the optic pathway and eyes to radiation is problematic in many long-term survivors. Yamaguchi *et al.*<sup>6, 7)</sup> reported the outcomes of 33 patients with stage I/II ENKL who were administered three cycles of 2/3DeVIC and extended-field RT. The 5-year OS rate was 73%, and local recurrence occurred in two patients (6.1%). However, 11 patients (33%) developed Grade 1 or 2 toxicities in the eye. In the present study, we treated patients having localized ENKL with the full-DeVIC regimen and a modified RT protocol. To avoid toxicities to normal tissue, we employed a smaller target volume than that used in previous DeVIC studies<sup>6, 7, 15)</sup>. This study described our experiences with the use of full-DeVIC combined with shrinking field RT for treating localized ENKL.

In this study, all patients were irradiated with a 4-6-MV photon beam. One patient was treated using X-ray simulation RT and two were treated with three-dimensional conformal RT (3D-CRT) (Fig. 1, Table 1). The prescribed radiation doses ranged from 50 to 60 Gy in daily fractions of 1.8-2.0 Gy. A mouth spacer and a two-step cone down technique were used to reduce local radiation toxicity. The first-step RT covered the tumor plus a prophylactic volume (Fig. 2). We defined first-step RT as “shrinking field RT.” The shrinking field comprised the radiation field of the prophylactic

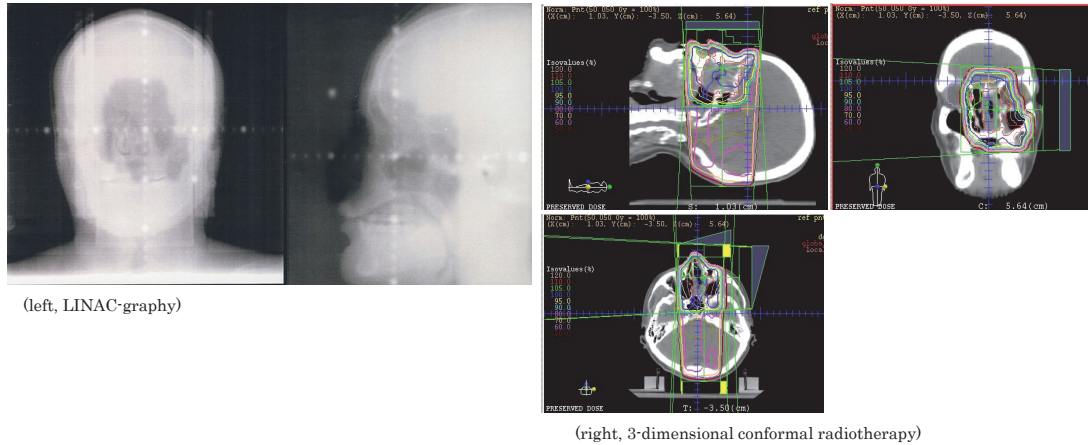


Fig. 1. **[legend]** LINAC-graphy (left) and 3-dimensional conformal radiotherapy (right) showing dose distribution in case 2 of localized nasal extranodal natural killer/T-cell lymphoma.

Table 1. Summary of treatment and outcomes in our cases (n=3)

No.	Radiotherapy technique (dose)	Regimens of first concurrent chemotherapy (Initiation time)	Initial response	Local recurrence post RT	Distant recurrence period (months, time from last course of radiation)	Observation period (months)	Acute toxicities
1	X-ray simulation (50 Gy)	full-DeVIC × 2 (Precedent combination of the radiotherapy)	PR (local)	No	Para-aortic LN, Stomach (1 m), Liver, Spleen (3 m)	5	Grade 1 mucositis and Grade 1 dermatitis
2	3D-CRT (50 Gy)	full-DeVIC × 3 (Precedent combination of the radiotherapy)	CR	No	No	106	Grade 1-2 mucositis and Grade 1 dermatitis
3	3D-CRT (60 Gy)	full-DeVIC × 4 (concurrent)	CR	No	Liver (5 m)	9	Grade 2-3 mucositis and Grade 1-2 dermatitis

Abbreviations: 3D-CRT; 3-dimensional conformal radiotherapy, DeVIC, dexamethasone, etoposide, ifosfamide, and carboplatin; RT, radiotherapy; PET, positron emission tomography; CR, complete response; PR, partial response

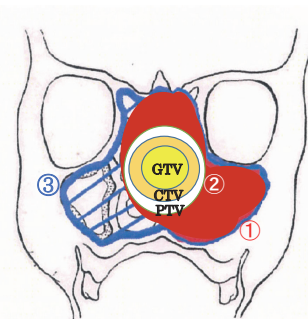
area, including the CTV, nasal cavity, nasopharynx, and ipsilateral paranasal sinuses (Fig. 2). All patients received additional radiation to the tumor area after completing first-step RT. For additional radiation to the tumor area, the CTV was defined as the GTV plus margins of 0.7-1.0 cm within the ipsilateral nasal cavity, paranasal cavities, and nasopharynx (Fig. 2). The planning target volume comprised the CTV plus a 0.5-cm margin (Fig. 2).

#### Cases treated with the modified radiation field

This retrospective study was approved by the Institutional Board of our university (number 2788). Informed consent was obtained from all

patients before treatment. Between August 2007 and March 2011, three patients with localized ENKL were administered RT in our hospital. Their ages ranged from 27 to 49 years, and their performance status ranged from 0 to 2. All diagnoses were pathologically confirmed as ENKL based on the morphological criteria of the World Health Organization classification<sup>1, 18-21)</sup>. Immunohistochemical analysis confirmed positive CD56 expression and negative CD20 expression in localized ENKL cells. Fluorescence in situ hybridization for Epstein-Barr virus (EBV)-encoded early small RNA (EBER) was performed to determine the EBV infection status. At the time

	RT field	RT dose (Gy/fraction)
<b>Our hospital</b> ①,②	· CTV: GTV with a margin > 0.7-1.0 cm + the ipsilateral nasal cavity and ipsilateral paranasal sinuses. · PTV: CTV with a 0.5-cm margin.	Stage I E : 50-60 / 25-30
<b>JCOG0211</b> ③	· CTV: GTV with a margin > 2.0 cm + the entire nasal cavity and bilateral paranasal sinuses. · PTV: CTV with a 0.5-cm margin ※ Note: For stage II E disease, PTV included the area of the involved cervical lymph node.	Stage I E : 50 / 25 Stage II E : 50.4 / 28



Abbreviations: RT, radiotherapy; GTV, gross tumor volume; CTV, clinical target volume; PTV, planning target volume

#### Schema:

① **Our hospital (red)** : First-step RT covered the tumor plus a prophylactic volume (shrinking field).  
 ② **Our hospital (white)** : Additional radiation to the tumor area.  
 ③ **JCOG0211 (blue)** : PTV.

Fig. 2. [legend] Comparison between the radiation field with our two-step cone down technique (shrinking field) and the radiation field in the JCOG0211 study (left).

Our two-step cone down technique (shrinking field) and the JCOG0211 study of the radiation field showing plans for one patient with localized nasal extranodal natural killer/T-cell lymphoma (right).

Schema is shown, ① Our hospital (red) : First-step RT covered the tumor plus a prophylactic volume (shrinking field), ② Our hospital (white) : Additional radiation to the tumor area, ③ JCOG0211 (blue) : PTV.

[Abbreviations] RT, radiotherapy; GTV, gross tumor volume; CTV, clinical target volume; PTV, planning target volume

Table 2. Clinical characteristics (n=3)

No.	Age (years)	Sex	Ann Arbor Stage	IPI score	NK-PI	B symptoms	CT and MRI (2007~ PET/CT)	bone marrow biopsy	Immunohistochemical expression	RNA (EBER)
1	27	Male	IE	Low	Group 2	–	One side of paranasal sinuses	Not involvement	CD20–, CD56 +	+
2	49	Male	IE	Low	Group 1	–	One side of nasal cavity	Not involvement	CD20–, CD56 +, TIA-1+, CD30+/-, CD3 ε +	+
3	35	Male	IE	Low	Group 1	–	One side of nasal cavity	Not involvement	CD20–, CD56 +	+

Abbreviations: IPI, International Prognostic Index; Int., Intermediate; NK-PI, natural killer/T-cell lymphoma prognostic index<sup>23)</sup> CT and MRI, computed tomography and magnetic resonance imaging; PET/CT, 18F-fludeoxyglucose positron emission tomography; EBER, Epstein-Barr virus-encoded small RNA

of diagnosis, computed tomography and magnetic resonance imaging of the involved sites and bone marrow biopsy were performed for staging, when possible. 18F-fludeoxyglucose positron emission tomography was performed since 2007. Staging was performed based on the Ann Arbor staging system<sup>1-3)</sup>. Patients with contiguous involvement extending to adjacent tissues or organs were defined as having stage IE disease. The Eastern Cooperative Oncology Group performance status, physical examinations, systemic B symptoms,

complete blood count, biochemical profiles, and serum lactate dehydrogenase levels were evaluated. Evaluation of International Prognostic Index and NK/T-cell lymphoma Prognostic Index<sup>22, 23)</sup> showed good prognostic factors (International Prognostic Index score: low; Natural Killer/T-cell Lymphoma Prognostic Index<sup>23)</sup>: Group 1-2) for all patients. We showed results in Table 2. The CRT regimens administered to our patients are summarized in Table 1. All patients received the full-DeVIC regimen (40 mg/d dexamethasone intravenously on

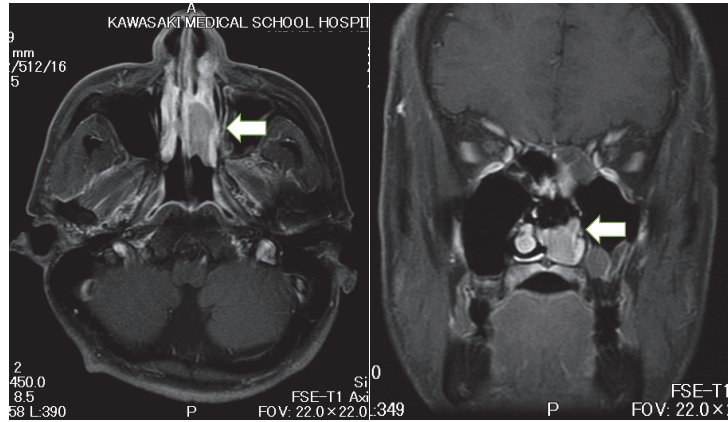


Fig. 3. [legend] Case2, contrast magnetic resonance imaging (left: axial, right: coronal) of paranasal sinuses demonstrating tumor: An  $30 \times 14 \times 21$ mm size (white arrow), and edema of nasopharyngeal mucosa.

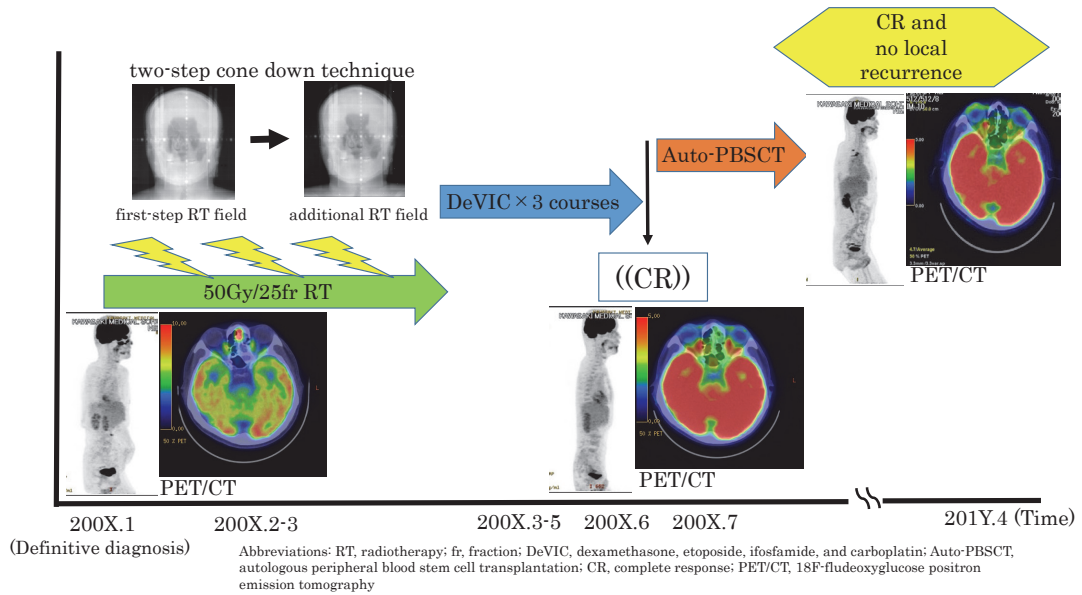


Fig. 4. [legend] Case 2 was administered combination of precedent RT (50Gy) to the nasal cavity and autologous peripheral blood stem cell transplantation after full-DeVIC. We showed PET/CT of each timing of orthodontic treatment.

[Abbreviations] RT, radiotherapy; fr, fraction; DeVIC, dexamethasone, etoposide, ifosfamide, and carboplatin; Auto-PBSCT, autologous peripheral blood stem cell transplantation; CR, complete response; PET/CT, 18F-fludeoxyglucose positron emission tomography

days 1-3,  $100 \text{ mg/m}^2$  etoposide intravenously over 2 h on days 1-3;  $1.5 \text{ g/m}^2$  ifosfamide intravenously over 3 h on days 1-3; and  $300 \text{ mg/m}^2$  carboplatin intravenously over 30 min on day 1). Patients with localized ENKL were considered candidates for radical RT. Only case 3 were administered concurrent CRT regimens.

After RT, the patients were followed up and evaluated at 1- to 3-month intervals. Local recurrence was pathologically confirmed. The patients underwent 18F-fludeoxyglucose positron emission tomography-computed tomography and magnetic resonance imaging (MRI) to evaluate treatment response. The tumor responses were

assessed according to Cheson's criteria<sup>20)</sup>. Toxicities were evaluated using the Common Terminology Criteria for Adverse Events, version 4.0<sup>21)</sup>.

#### <Case 1>

Case 1 was administered precedent combination of RT (50Gy) to the nasal cavity and achieved local control with partial response but developed stomach, liver, and spleen invasion at 1-3 months after RT and died 5 months after RT. The patient's outcomes are summarized in Table 1.

#### <Case 2>

Although not recommended in the latest guidelines from the Japanese Society of Hematology<sup>24)</sup>, this patient underwent autologous peripheral blood stem cell transplantation after full-DeVIC. With or without association with the transplant, there was not a recurrence during 106 months. Case 2 experienced acute Grade 1-2 mucositis and Grade 1 dermatitis but did not experience late toxicity. We showed MRI and clinical course of case 2 to Fig. 3 and 4.

#### <Case 3>

The survival period of Case 3 was 9 months. Despite achieving CR, this case experienced liver invasion in the fifth month after concurrent CRT. Regarding safety, the patient experienced acute Grade 2-3 mucositis and Grade 1-2 dermatitis associated with concurrent CRT. The patient received full-DeVIC and four courses of RT in another hospital, and it becomes the changing hospital in this hospital, and the fact is unknown subsequently. However, it is a case of 2007 before the guidelines induction, and reasons include that the therapies in each institution were not unified when full-DeVIC guesses a reason performed four courses in. However, shrinking field RT administered by the other hospital was similar to that administered in our institution.

## DISCUSSION

We showed treatment eras among patients with newly diagnosed ENKL treated in Japan (Fig. 5). In the past, radiotherapy alone has been chosen. Also, there were the treatment eras when radiotherapy preceded before chemotherapy and was performed.

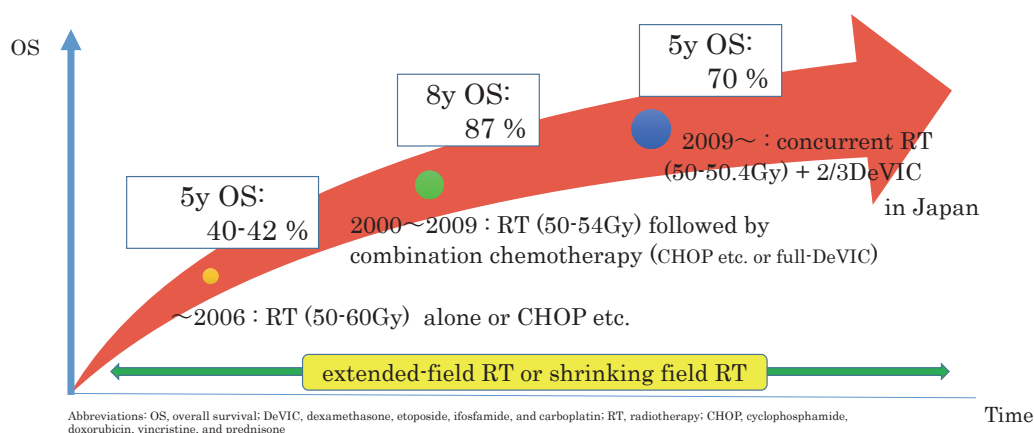


Fig. 5. [legend] The RT and/or chemotherapy according to treatment eras among patients with newly diagnosed ENKL treated in clinical practice. The different rates of overall survival (OS) in individual eras, 40 to 42% of 5y OS<sup>5, 25)</sup> until 2006, 87% of 8y OS<sup>26, 27)</sup> during 200 to 2009, and 70% of 5y OS<sup>7)</sup> since 2009 are schematically shown.

[Abbreviations] OS, overall survival; DeVIC, dexamethasone, etoposide, ifosfamide, and carboplatin; RT, radiotherapy; CHOP, cyclophosphamide, doxorubicin, vincristine, and prednisone



However, they consisted of the collection of the low report of the evidence level.

In 2013, the combination of 2/3DeVIC therapy and RT became the standard treatment for localized ENKL in Japan, which dramatically increased the average patient survival time. The reasons for using shrinking field RT in our institution included avoiding RT-associated adverse events when treating localized ENKL and increasing survival. The localized fields used at our institution were smaller than those used in the JCOG0211 study. Based on the three cases described in this review, it was difficult to evaluate the effects of shrinking field RT because we could evaluate only three patients, two of whom died because of distant metastases within 1 year. Moreover, the one case with long-term survival underwent stem cell transplantation, which was not recommended in the 2018 guidelines<sup>24)</sup>. Clinical evaluation of shrinking field RT is currently not possible.

Increased numbers of cases are required; however, this is difficult to achieve owing to the low incidence rate of this disease in single institutions.

In contrast, it may be necessary to think about making a proposal for JCOG, and switching from present JCOG0211 toward shrinking field RT for localized ENKL in institution and others. Because it is difficult to distinguish between normal tissue (e.g., eyes, central nervous system, mucosa) and organs in the head and neck owing to their complicated structures, these targets are often treated using extended-field RT. However, extended-field RT increases the risk of adverse events and reduces a patient's quality of life. Thus, we applied shrinking field RT to prevent negative effects on a patient's quality of life.

Second, adverse events (mucositis, optic neuritis, myelosuppression) may develop following concurrent CRT for treating localized ENKL. Thus, shrinking field RT was applied to reduce the occurrence of these adverse events. To avoid normal

tissue toxicities, we utilized a smaller shrinking field than that used in the JCOG0211 study (Fig. 2). In the JCOG0211 study, one patient developed RT-associated Grade 4 dermatitis (paranasal skin necrosis and perforation)<sup>8)</sup>. The shrinking field RT used in our institution could potentially avoid the development of Grade 4 acute radiation toxicity.

However, as the present study included only three cases, it was difficult to prove this effect. As for the future prospects, number of cases aims for it being to 10 in a shrinking field RT that we introduced this time.

## CONCLUSION

We evaluated the effects of using a modified shrinking field RT regimen in CRT for treating localized ENKL. The localized fields used at our institution were smaller than those specified in the JCOG0211 protocol. We observed good local control for this shrinking field RT regimen for localized ENKL. Furthermore, no serious toxicity was observed. Now still, a report of shrinking field or extended-field RT is accomplished, and a debate to decide which fields are appropriate is not accompanied by the end. This study described our experiences with a regimen comprising DeVIC combined with shrinking field RT for treating localized ENKL.

## DISCLOSURE

The authors report no conflicts of interest related to this work.

## REFERENCES

- 1) Vose J, Armitage J, Weisenburger D, International T-cell Lymphoma Project: International peripheral T-cell and natural killer/T-cell lymphoma study: pathology findings and clinical outcomes. *J Clin Oncol* 26: 4124-4130, 2008
- 2) Kwong YL: The diagnosis and management of extranodal NK/T-cell lymphoma, nasal-type and aggressive NK-cell leukemia. *J Clin Exp Hematop* 51:

- 21-28, 2011
- 3) Yamaguchi M: Current and future management of NK/T-cell lymphoma based on clinical trials. *Int J Hematol* 96: 562-571, 2012
  - 4) Yang Y, Zhu Y, Cao JZ, *et al.*: Risk-adapted therapy for early-stage extranodal nasal-type NK/T-cell lymphoma: analysis from a multicenter study. *Blood* 126: 1424-1432, 2015
  - 5) Kim GE, Cho JH, Yang WI, *et al.*: Angiocentric lymphoma of the head and neck: patterns of systemic failure after radiation treatment. *J Clin Oncol* 18: 54-63, 2000
  - 6) Yamaguchi M, Tobinai K, Oguchi M, *et al.*: Phase I / II study of concurrent chemoradiotherapy for localized nasal natural killer/T-Cell lymphoma: Japan Clinical Oncology Group Study JCOG0211. *Clin Oncol* 27: 5594-5600, 2009
  - 7) Yamaguchi M, Tobinai K, Oguchi M, *et al.*: Concurrent chemoradiotherapy for localized nasal natural killer/T-cell lymphoma: an updated analysis of the Japan clinical oncology group study JCOG0211. *J Clin Oncol* 30: 4044-4046, 2012
  - 8) Yamaguchi M, Suzuki R, Oguchi M, *et al.*: Treatments and Outcomes of Patients With Extranodal Natural Killer/T-Cell Lymphoma Diagnosed Between 2000 and 2013: A Cooperative Study in Japan. *J Clin Oncol* 35: 32-39, 2017
  - 9) Hattori Y, Murai T, Iwata H, Uchiyama K, Mimura M, Kato E, Murata R, Shibamoto Y: Chemoradiotherapy for localized extranodal natural killer/T-cell lymphoma, nasal type, using a shrinking-field radiation strategy: multi-institutional experience. *Jpn J Radiol* 34: 292-299, 2016
  - 10) Wang L, Wang ZH, Chen XQ, Li YJ, Wang KF, Xia YF, Xia ZJ: First-line combination of gemcitabine, oxaliplatin, and L-asparaginase (GELOX) followed by involved-field radiation therapy for patients with stage IE/IIe extranodal natural killer/T-cell lymphoma. *Cancer* 119: 348-355, 2013
  - 11) Jiang M, Zhang H, Jiang Y, *et al.*: Phase 2 trial of "sandwich" L-asparaginase, vincristine, and prednisone chemotherapy with radiotherapy in newly diagnosed, stage IE to IIe, nasal type, extranodal natural killer/T-cell lymphoma. *Cancer* 118: 3294-3301, 2012
  - 12) Oh D, Ahn YC, Kim SJ, Kim WS, Ko YH: Concurrent chemoradiation Therapy Followed by Consolidation Chemotherapy for Localized Extranodal Natural Killer/T-Cell Lymphoma, Nasal Type. *Int J Radiat Oncol Biol Phys* 93: 677-683, 2015
  - 13) Li YX, Wang H, Jin J, *et al.*: Radiotherapy alone with curative intent in patients with stage I extranodal nasal-type NK/T-cell lymphoma. *Int J Radiat Oncol Biol Phys* 82: 1809-1815, 2012
  - 14) Luo J, Cao C, Zhu Y, Liu P, Liu L, Lu K, Lhang N, Zhou N: Chemotherapy combined with high-dose extended-field radiotherapy for stage I extranodal nasal-type natural killer/T-cell lymphoma. *Onco Targets Ther* 11: 6147-6150, 2016
  - 15) Isobe K, Uno T, Tamaru J, Kawakami H, Veno N, Wakita H, Okada J, Itami J, Ito H: Extranodal natural killer/T-cell lymphoma, nasal type: the significance of radiotherapeutic parameters. *Cancer* 106: 609-615, 2006
  - 16) Lin N, Song Y, Zheng W, *et al.*: A prospective phase II study of L-asparaginase- CHOP plus radiation in newly diagnosed extranodal NK/T-cell lymphoma, nasal type. *J Hematol Oncol* 6: 44, 2013
  - 17) Kim SJ, Kim K, Kim BS, *et al.*: Phase II trial of concurrent radiation and weekly cisplatin followed by VIPD chemotherapy in newly diagnosed, stage IE to IIe, nasal, extranodal NK/T-cell Lymphoma: Consortium for improving Survival of Lymphoma study. *J Clin Oncol* 27: 6027-6032, 2009
  - 18) Swerdlow SH, Campo E, Harris NL, Jaffe ES, Pileri SA, Steir H, Thiele J, Vardiman JW: WHO Classification of Tumours of Haematopoietic and Lymphoid Tissues. Lyon, France, IARC. 2017
  - 19) Chan JK, Quintanilla-Martinez L, Ferry JA, *et al.*: Extranodal NK/T-cell lymphoma, nasal type. In: Swerdlow SH, Campo E, Harris NL, *et al.*: (eds). WHO Classification of Tumours of Haematopoietic and Lymphoid Tissues. Lyon: IARC, 285-288, 2008
  - 20) Cheson BD, Pfistner B, Juweid ME, *et al.*: Revised response criteria for malignant lymphoma. *J Clin Oncol* 25: 579-586, 2007
  - 21) Common Terminology Criteria for Adverse Events (CTCAE) Version 4.0. Published: May 28, 2009 (v4.03: Jun. 14, 2010) by National Cancer Institute (NCI), Cancer Therapy Evaluation Program (CTEP).
  - 22) International Non-Hodgkin's Lymphoma Prognostic Factors Project. A predictive model for aggressive non-Hodgkin's lymphoma. *N Engl J Med* 329: 987-994, 1993
  - 23) Lee J, Suh C, Park YH, *et al.*: Extranodal natural killer



- T-cell lymphoma, nasal-type: a prognostic model from a retrospective multicenter study. *J Clin Oncol*: 24: 612-618, 2006
- 24) 日本血液学会：造血器腫瘍診療ガイドライン2018年版. 東京, 金原出版, 2018
- 25) Koom WS, Chung EJ, Yang WI, *et al.*: Angiocentric T-cell and NK/T-cell lymphomas: radiotherapeutic viewpoints. *Int J Radiat Oncol Biol Phys* 59: 1127-1137, 2004
- 26) Aviles A, Diaz N.R, Neri N, *et al.*: Angiocentric nasal T/natural killer cell lymphoma: a single centre study of prognostic factors in 108 patients. *Clin Lab Haematol* 22: 215-220, 2000
- 27) Yamaguchi M, Ogawa S, Nomoto Y, *et al.*: Treatment outcome of nasal NK-cell lymphoma: a report of 12 consecutively diagnosed cases and a review of the literature. *J Clin Exp Hematop* 41: 93-99, 2001