

## Benign Adult Familial Myoclonic Epilepsy (BAFME)

Takeshi YASUDA

*Department of Neurology, Kawasaki Medical School,  
Kurashiki 701-01, Japan*

*Accepted for publication on January 22, 1992*

**ABSTRACT.** Fourteen of the 26 members of two families with hereditary myoclonic epilepsy were studied, and the following findings were obtained.

The disease was transmitted by autosomal dominant inheritance, and the onset was observed after adolescence with tremulous finger movement and/or myoclonus of the extremities. The clinical course was non-progressive and neither dementia nor cerebellar ataxia developed during observation of over 10 years. The myoclonus appeared predominantly in the four extremities, not only at rest but also on posturing or in action, and it was increased by fatigue, insomnia or photic stimulations. Epileptic seizures appeared in 12 patients, though the frequency of seizures was relatively rare. Usually, increased diffuse myoclonic jerks were followed by generalized tonic-clonic convulsions. Electroencephalograms showed generalized spikes or polyspikes and wave complexes, and some patients exhibited photosensitivities. The amplitudes of somatosensory and visual evoked potentials increased, and the C reflex, which is a long-loop reflex, could be recorded in all cases at rest. By the jerk-locked averaging method, a positive spike time-locked to the myoclonic jerk was demonstrated in four patients before 15-20 msec of myoclonic jerk. These findings indicated "cortical reflex myoclonus". Valproates were markedly effective for its treatment.

I proposed the new term "benign adult familial myoclonic epilepsy (BAFME)" for this disease.

**Key words:** myoclonic epilepsy — cortical reflex myoclonus — autosomal dominant inheritance — C reflex — valproic acid

A variety of conditions have been included in myoclonic epilepsy, but the majority are generally progressive, are accompanied by dementia and cerebellar ataxia, and have a poor prognosis.<sup>1)</sup> However, there are myoclonic epilepsies which are not progressive and which have benign courses, such as juvenile myoclonic epilepsy (JME).<sup>2)</sup> The disease described in this study showed inherited myoclonus and epilepsy as primary symptoms, and both symptoms closely correlated with each other. The disease responded well to anticonvulsants and was non-progressive in most patients in a follow-up over 10 years. A number of diseases resembling this disease have been reported in the past, but the nomenclatures were problematic. I propose that this disease should be called "benign adult familial myoclonic epilepsy (BAFME)" and describe its clinical symptoms, electrophysiologic features, clinical classification, and treatment.

## SUBJECTS

Two families with hereditary myoclonic epilepsy were studied (Fig. 1). In both of these families, the disease was observed through three generations. A total of 26 patients (19 in Family A and 7 in Family B) were confirmed, and direct examination and various tests were carried out in 14 patients (12 in Family A and 2 in Family B). Both families were from Okayama Prefecture, but no relationship between the two families has been established to date. The proband in Family A is described first.

**Case Y. O.:** This 67-year-old female (AII-4) had a chief complaint of episodes of loss of consciousness accompanied by convulsion. She had undergone surgery for gallstones at the age of 56. The present illness began at the age of 27 with fine tremulous finger movements and twitching of the upper and lower extremities (myoclonus) at times of fatigue. The first episode of generalized

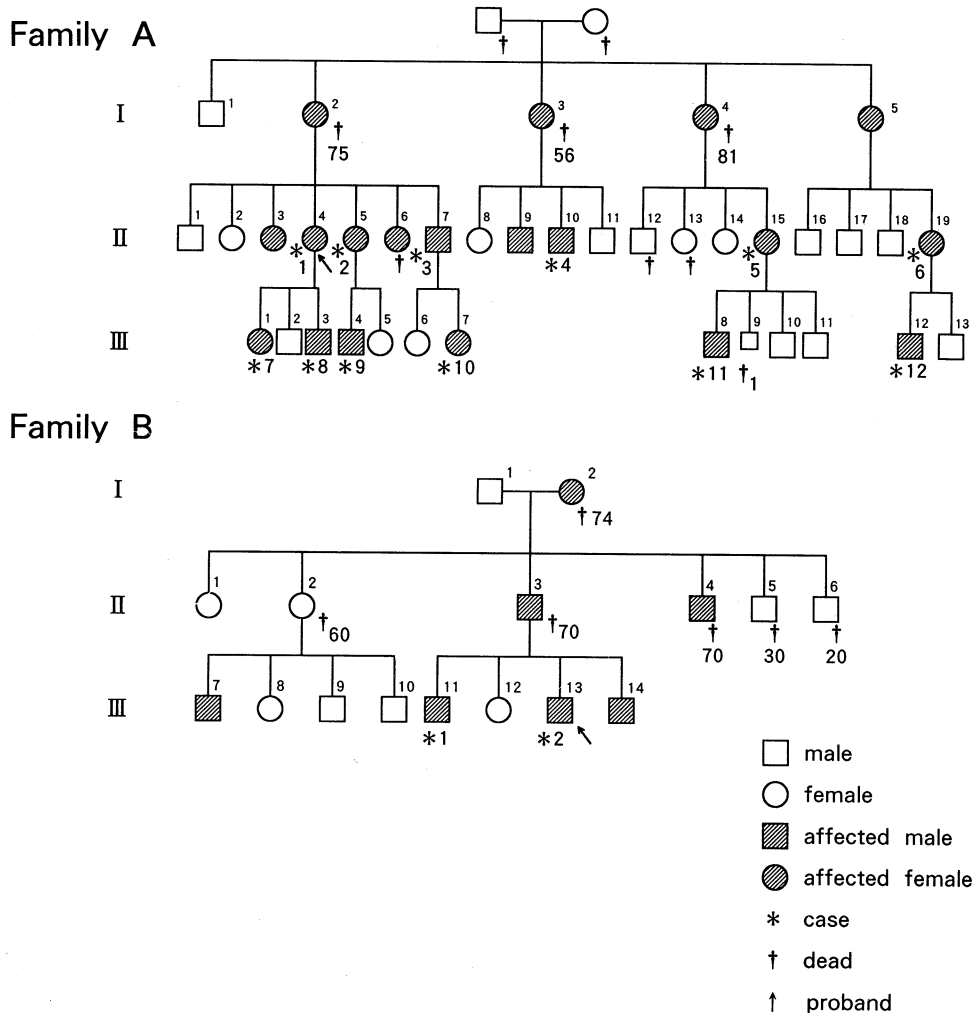



Fig. 1. Pedigrees of families A and B



Y. O. 46y.o. M. (A88451) (Case 14, Bill-13)

Y. O. 57y.o. F. (A97363) (Case 1, AII-4)

Y. O. 57y.o. F. (A97363) (Case 1, AII-4)

Fig. 2. EEG. A; polyspikes and wave complexes B; photo-induced occipital spikes C; photomyoclonic responses

tonic-clonic convulsion occurred with exacerbation of this myoclonus. Anticonvulsants were prescribed by a doctor at another hospital. Although she took them regularly, similar attacks recurred four or five times a year when she was tired. The frequency of attacks increased after she underwent surgery for gallstones. Attacks were induced when she was exposed to sunlight, and the patient became unable to go outdoors due to attacks occurring two or three times a day. She was hospitalized in our department on June 30, 1980.

**[Findings on admission]** There were no particular findings from general physical examinations. Neurological findings included myoclonus in the upper and lower extremities occurring at rest, with changing body position, and during activity, and relatively irregular fine tremulous movements in the fingers but no clouding of consciousness or dementia. However, deep tendon reflexes were normal, and no morbid reflexes, ataxia, or sensory disorders were noted.

**[Clinical laboratory findings]** The peripheral blood profile, general biochemical findings, and urinary and fecal examinations were all normal. No vacuolation was noted in peripheral lymphocytes. Head CT findings were normal. Electroencephalograms (EEGs) showed generalized spikes or polyspikes and wave complexes, and photic stimulation induced marked photoconvulsive responses (Fig. 2). Somatosensory evoked potentials (SEPs) recorded by stimulation of the median nerve at the wrist showed marked increases in  $P25$  and  $N33$  to  $45 \mu\text{V}$ , and a C reflex, a long-loop reflex, could be induced with a latency of 42 msec at rest from the ipsilateral thenar muscle by stimulation at the same site.

**[Clinical course]** During hospitalization, drugs including phenytoin (PHT), amobarbital, clomipramine, and cloxazolam were administered in decreasing doses, but myoclonus and tremulous finger movements were only alleviated by the administration of sodium valproate (VPA) at 600 mg/day and diazepam (DZP) at 6 mg/day. The patient was discharged on September 27, 1980, and has been followed up to date in the outpatient clinic with the same regimen. Presently, myoclonus and attacks of convulsion are completely absent, and the patient has no difficulty in activities of daily living.

## RESULTS

### 1. Neurological findings

In Families A and B, there were a total of 26 patients, consisting of 13 males and 13 females. Of the seven patients who had died before the study, the mean age of death was 71.2 years for the five patients whose ages at death were known. Fourteen of these patients, (eight males and six females) were examined. In these patients, tremulous finger movements and myoclonus occurred between the ages of 18 and 45 years (mean 30.5 years), often followed by attacks of epilepsy. Myoclonus was observed not only at rest but also with changing body position and during action. It was observed in both the upper and lower extremities, but was more pronounced in the upper extremities. In some patients, it was also seen in the eyelids and the abdomen. Myoclonus was often aggravated by fatigue and insomnia and occasionally by bright light, surgery and pregnancy. Attacks of convulsions were noted in 12 of the 14 patients with the onset between the ages of 24 and 49 years (mean 35.7 years).

TABLE. 1. Characteristics in 14 patients with BAFME

Case	Family	Age	Sex	Age at onset		Site of myoclonus	Provoking factors of myoclonus	Frequency of epileptic seizure	EEG	SEP (P <sub>25</sub> -N <sub>33</sub> )	VEP
				tremulous finger movement	epileptic seizure						
1.	II-4	67	F	27	27	U/E, L/E	fatigue, light, operation	4-5/y	PSWC, PES	45 $\mu$ V	large
2.	II-5	65	F	30	30	U/E, L/E, abdomen	fatigue	4	PSWC	55 $\mu$ V	large
3.	II-7	57	M	30	30	U/E	insomnia, fatigue	2	S	35 $\mu$ V	
4.	II-10	54	M	38	38	U/E, L/E	insomnia, fatigue	3-4/y	PSWC	30 $\mu$ V	large
5.	II-15	65	F	45	45	U/E	insomnia, fatigue	3	PSWC	38 $\mu$ V	
6.	II-9	53	F	45	45	U/E	fatigue, light	2	PSWC	35 $\mu$ V	
7.	III-1	45	F	(-)	31	U/E, palpebra	fatigue	1	PSWC	27 $\mu$ V	
8.	III-3	39	M	24	24	U/E	fatigue, insomnia	3	PSWC, PMR	30 $\mu$ V	
9.	III-4	41	M	25	25	U/E	fatigue	1	S (mild)	20 $\mu$ V	large
10.	III-7	30	F	26	26	(-)	pregnancy, fatigue	0	PSWC	35 $\mu$ V	
11.	III-8	43	M	22	22	U/E	fatigue	1	S	30 $\mu$ V	large
12.	III-12	25	M	18	18	(-)	fatigue	0	SWC	30 $\mu$ V	
Family B											
13.	III-11	59	M	29	35	U/E, L/E	fatigue, light	2	PSWC, PMR	40 $\mu$ V	large
14.	III-13	51	M	23	30	U/E, L/E, palpebra	welding light, fatigue	1	PSWC, PMR	30 $\mu$ V	large

U/E : upper extremities, L/E : lower extremities  
 PSWC : polyspikes and wave complex, PES : photo-evoked spike, PMR : photomyoclonic response  
 SWC : spikes and wave complex, S : spike

In many patients, generalized myoclonus was aggravated to generalized tonic-clonic convulsions. The frequency of epileptic attacks was generally low, often totaling only one to four times through the lifespan. Tremulous finger movement was observed with the changing of body position and during action and was aggravated by mental stress.

## 2. Laboratory findings

Electrophysiologically, EEGs were abnormal in all 14 patients. Polyspikes and wave complexes were observed in many patients, and only spikes were noted sporadically in three patients. Photomyoclonus was induced by photic stimulation in three patients, and marked photo-induced spikes were noted in the occipital region in one patient (Fig. 2). The amplitude of the  $\overline{P25}$  and  $\overline{N33}$  components of SEP was increased (20-55  $\mu$ V) by stimulation of the median nerve at the wrist in all 14 patients (Fig. 3), and the amplitude of the  $\overline{N75}$ ,  $\overline{P100}$ ,  $\overline{N145}$  components was increased by photic stimulation in all seven patients in whom visual evoked potentials (VEPs) were recorded (Fig. 4). A C reflex with a latency of 38-45 msec could also be recorded in all patients from the thenar muscle by electric stimulation of the ipsilateral median nerve at the wrist (Fig. 3). Furthermore, positive spikes preceding myoclonus by 15-20 msec were observed in the centro-parietal region on the contralateral side of myoclonus in four patients by the jerk-locked averaging method using myoclonus of the upper extremity as a trigger (Fig. 5). From these results, the myoclonus of this disease is considered to be "cortical reflex myoclonus".<sup>3)</sup> Surface electromyographic analysis indicated that the myoclonus had a short duration of about 20 msec and appeared nearly simultaneously in the agonist and antagonist muscles (Fig. 6). Accelerometric analysis of the tremulous finger movements allowed classification into two types; one with a relatively stable frequency of *ca.* 9-10 Hz and one more variable in frequency (Fig. 7). Head CT was performed in all patients, but no abnormalities were noted except mild cerebral cortical atrophy in three patients. The levels of both lactate and pyruvate in serum and liquor were within normal limits.

## 3. Treatment

VPA (600-1,200 mg/day) was markedly effective in all patients. It was replaced with clonazepam (CZP, 3 mg/day) in one patient, because side effects were suspected. CZP was also found to be effective in this patient. Since intravenous infusion of DZP simultaneously reduced the amplitude of SEP and alleviated myoclonus, it was used in a small dose (6 mg/day) with VPA in some patients. The C reflex was the most sensitive index of the therapeutic effect against myoclonus. Myoclonus was reduced, but tremulous finger movements persisted in five patients after treatment with VPA. A small dose of propranolol (30-60 mg/day) was effective against these persistent tremulous finger movements.

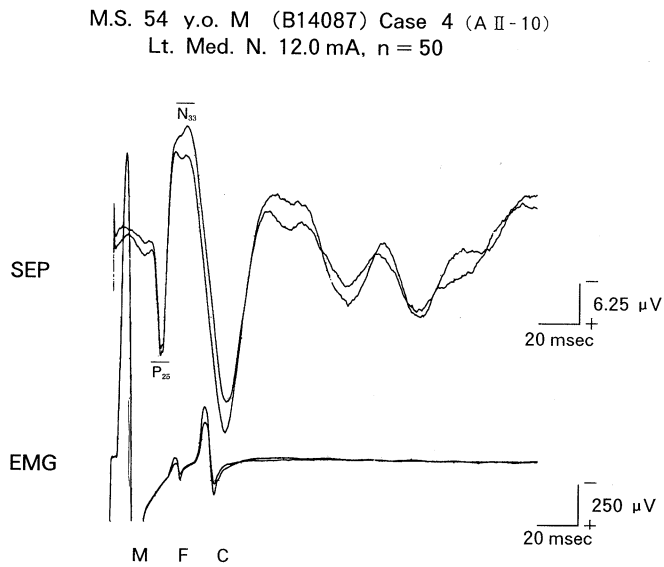


Fig. 3. SEP and EMG. The amplitude of the  $\overline{P25}$  and  $\overline{N33}$  of SEP was increased by stimulation of the median nerve at the wrist and the C reflex (long-loop reflex) could be recorded.

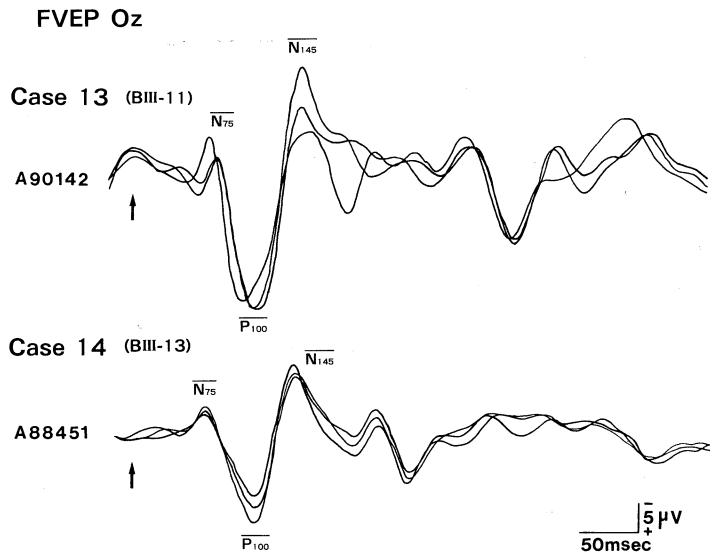


Fig. 4. Flash VEP. The amplitude of the  $\overline{N75}$ ,  $\overline{P100}$ ,  $\overline{N145}$  of VEP was increased by photic stimulation.

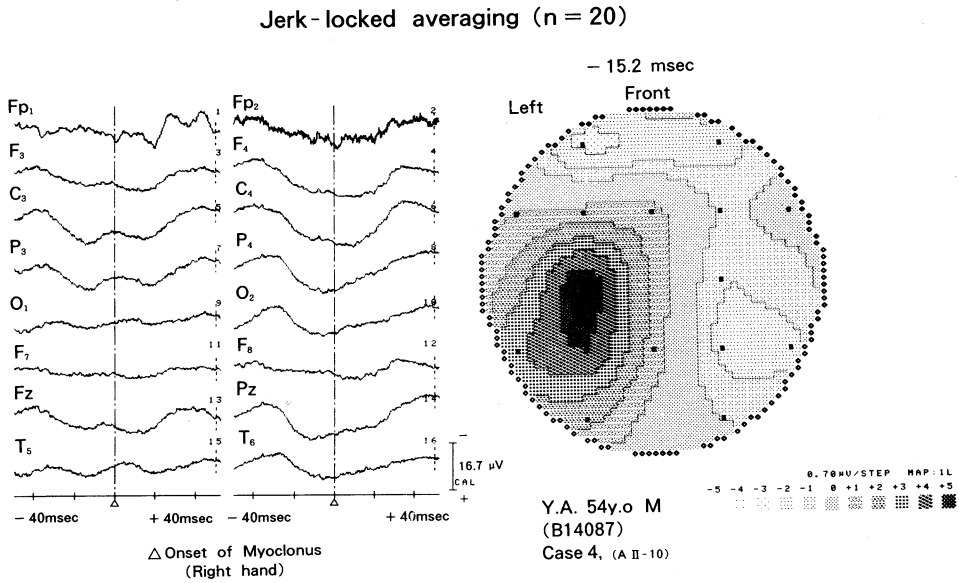


Fig. 5. Scalp topography of a myoclonus-related positive spike (myoclonus from right thenar muscle)

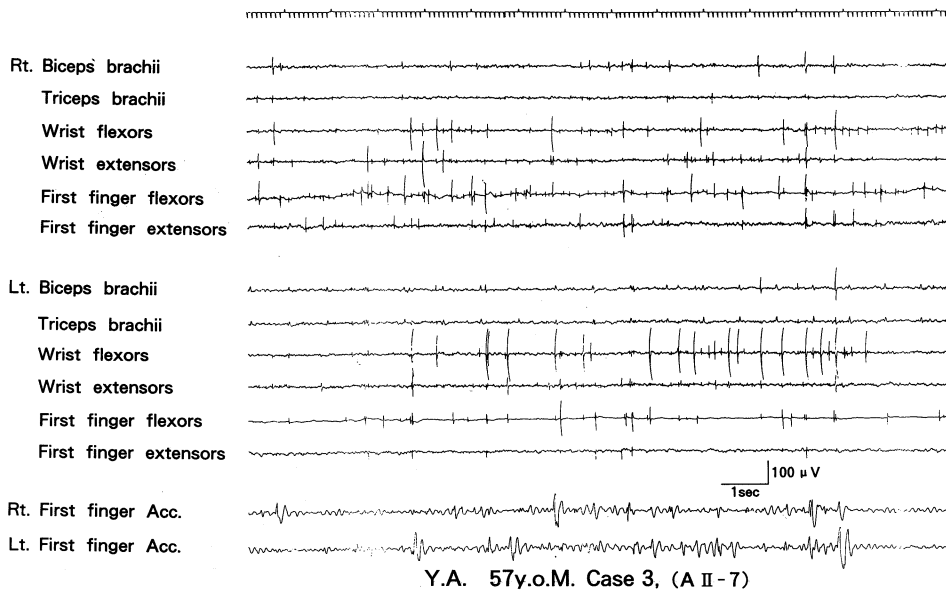
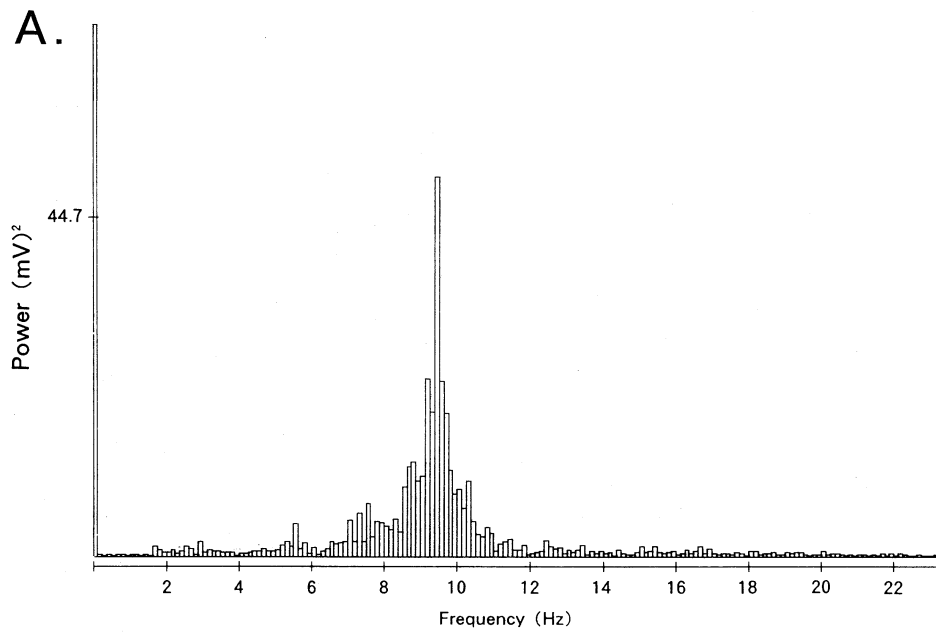
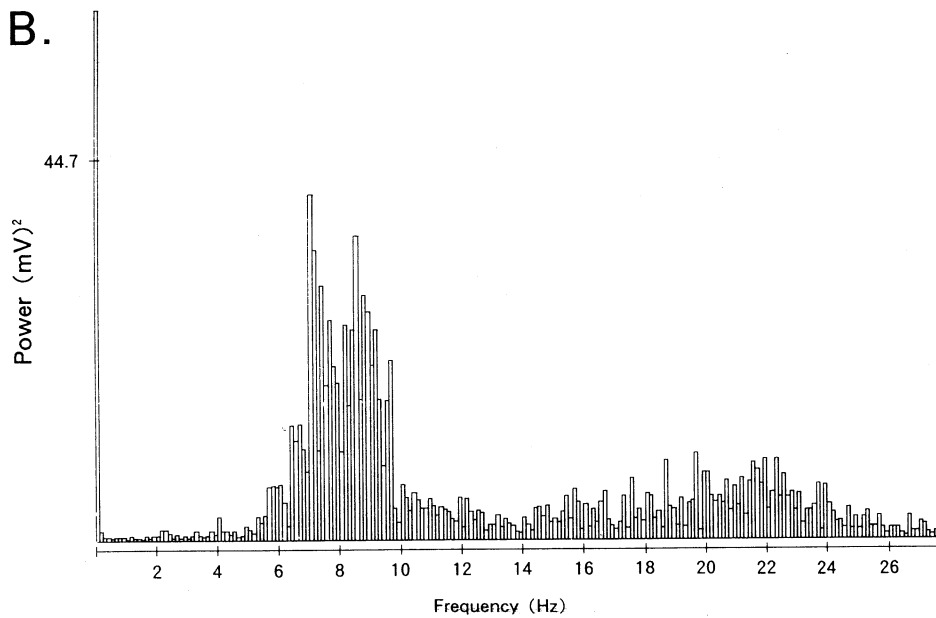


Fig. 6. Surface EMG. Bottom; accereometric analysis of tremulous finger movements





T. N. 43y.o. M(B21943)Case 11, (A III-8)



Y. A. 57y.o. M(B6007)Case 3, (A II-7)

Fig. 7. Accelerometric frequency analysis of tremulous finger movements showed two types. A; rhythmical one with a frequency of ca. 9.5 Hz, B; a nonrhythmical one

## DISCUSSION

The disease described here, BAFME, is transmitted by autosomal dominant inheritance and its onset is characterized by tremulous finger movements and myoclonus of the extremities after early adolescence. It occasionally produces generalized tonic-clonic convulsions but responds well to anticonvulsants, and the myoclonic epilepsy in this disease is known to be non-progressive on long-term follow-up.

Myoclonic epilepsy has been generally considered to be progressive, to cause dementia, cerebellar ataxia, or other extrapyramidal symptoms, and ultimately to have a poor prognosis.<sup>4)</sup> A long-term follow-up of BAFME, on the other hand, indicated that the disease responds well to anticonvulsants, causes neither dementia nor cerebellar ataxia, but allows many patients to have a normal lifespan, hence the expression "benign" was used. I also added "adult" to distinguish it from JME with the onset in youth. Marsden *et al.*<sup>5)</sup> referred to a myoclonic disease reported in 1899 by Rabot<sup>6)</sup>, as a benign familial myoclonic epilepsy. However, a study of the literature suggested that this condition is identical to JME. According to an analysis of 47 cases by Janz, the onset of JME was observed at ages ranging from 10 to 23 years, but it was observed between the ages of 14 and 18 years in 66% of the patients.<sup>7)</sup> In contrast, the age of onset of BAFME was after 24 years of age. Both JME and BAFME show myoclonus and convulsions as primary symptoms and respond remarkably to VPA, but they are transmitted by clearly different inheritance patterns. If JME were caused by genetic factors, it would not show the autosomal dominant inheritance shown by BAFME. Also, the conspicuous myoclonic jerks characteristically observed in JME after awaking are not seen in BAFME. The two diseases may be clearly distinguished by these two points.

In a group of diseases called progressive myoclonic epilepsy (PME), a variety of conditions have been included, and many familial diseases show autosomal recessive inheritance. On the other hand, those that show autosomal dominant inheritance are limited to dentato-rubro-pallido-luysian atrophy (DRPLA) and Kufs disease, which have been reported in one family.<sup>8)</sup> Myoclonus epilepsy with ragged red fiber (MERRF), PME accompanied by lipoma, and May-White syndrome may be transmitted by maternal inheritance.<sup>8)</sup> Differentiation of these diseases from DRPLA is important. Naito *et al.*<sup>9)</sup> considered that some families with DRPLA showed a benign course. But Inazuki *et al.*<sup>10)</sup> separated such family cases as "familial essential myoclonus and epilepsy (FEME)". They considered that the condition is a familial disease in which essential myoclonus is accompanied by epilepsy, and that a single gene expressed the two phenotypes of myoclonus and epilepsy. Their FEME and my BAFME appear to be nearly identical clinico-pathological entities, but I find some problems within the name "FEME". An important point is that the disease is never essential myoclonus<sup>11)</sup> concomitant with epilepsy. One diagnostic criterion of essential myoclonus is a long EMG burst of 50-100 msec<sup>12-14)</sup> but in the epileptic myoclonus of BAFME, the EMG burst is short, being 20 msec or less. We have confirmed the findings in our cases of essential myoclonus.<sup>13)</sup>

Moreover, in BAFME, generalized tonic-clonic convulsions are known to occur when myoclonus is aggravated and then spread to the whole body. This phenomenon is a further evidence of a close association between myoclonus and epilepsy. These findings clearly indicate that the disease is a myoclonic epilepsy and not a disease with both essential myoclonus and epilepsy. Also, cases which were considered to be identical to BAFME have been reported recently in addition to those we have described.<sup>15,16)</sup> Diseases that are transmitted by dominant inheritance without dementia nor cerebellar ataxia, and reveal non-progressive myoclonus and epileptic seizure have been reported to date,<sup>17-20)</sup> but I consider there is justification for excluding all these diseases from PME as different clinical entities. Both myoclonic epilepsy of Hartung type<sup>21,22)</sup> and hereditary (or familial) tremor associated with epilepsy<sup>23-25)</sup> may or may not be differentiated from BAFME. Concerning the former disease, Hartung reported the first two cases in 1920.<sup>21)</sup> This type also showed dominant inheritance and myoclonus and epilepsy were the primary symptoms. However, the age of its onset varies from infancy to middle age, a considerable variation is observed in its clinical severity within the same family, and neurological symptoms such as mental disorders, cerebellar ataxia, and spastic paraplegia are occasionally present. Moreover, an autopsy study revealed focal loss of neurons in the cerebrum and dentate nucleus of the cerebellum,<sup>23)</sup> so the term "benign" is inappropriate for this disease. Concerning the latter disease, the inheritance pattern and clinical symptoms are very similar to those of BAFME. However, electrophysiological evaluation has been insufficient in most of the past reports to determine whether the involuntary movement is myoclonus or tremor. BAFME may well be included in the conditions reported as hereditary tremor. In BAFME, tremulous finger movement is either relatively rhythmic with a frequency of *ca.* 9 to 10 Hz or more irregular and unrhythmic. These tremulous movements may be minipolymyoclonus<sup>26)</sup> or cortical tremor,<sup>27)</sup> and further evaluation is needed.

As for treatment, VPA and CZP are effective for the treatment of both epilepsy and myoclonus. A diagnosis of PME was made in the proband, but several attacks of generalized tonic-clonic convulsions were observed daily despite the treatment with PHT and psychotropic drugs. The patient was dramatically remitted from these symptoms after shifting the regimen to VPA alone, and no clinical symptoms have been noted over a follow-up of over 10 years. Thus, VPA or CZP is recommended as the first choice for the treatment of BAFME. In some of the patients treated with VPA, tremulous finger movements persisted after alleviation of myoclonus, and  $\beta$ -blockers were employed against these involuntary movements.

Since this disease responds very well to VPA or CZP, it may be overlooked as simply primary generalized epilepsy without a detailed familial study, precise clinical examination, and electrophysiological evaluation. Therefore, BAFME may not be a rare disease as has been reported to date.

I emphasize the importance of considering BAFME as a clinical entity which should be separated from PME. As the disease shows dominant inheritance, successful treatment based on genetic investigations is anticipated.

Society of Epilepsy (Kyoto, 1983), the 25th Conference of the Japanese Society of Neurology (Sapporo, 1984), the 19th Conference of the Japanese Society of Epilepsy (Otsu, 1985), the Annual Meeting of the American Epilepsy Society (Seattle, 1986), the 32nd Conference of the Japanese Society of Neurology (Tokyo, 1991), and the 8th Asian and Oceanian Congress of Neurology (Tokyo, 1991).

The author is deeply obliged to Professor Akira Terao, Department of Neurology, Kawasaki Medical School for his many valuable suggestions and helpful discussions throughout the course of this work and his many incisive comments on the manuscript. I also wish to thank to Professor Hiroshi Ishino, Department of Psychiatry, Shimane Medical University and Professor Hiroshi Shibasaki, Department of Brain Pathophysiology, Kyoto University, for their kind guidance, and Lecturer Sachio Kawashima, Department of Ophthalmology, Kawasaki Medical School for examination of VEP.

This study was supported in part by a Research Project Grant (No. 55-806) from Kawasaki Medical School.

#### REFERENCES

- 1) Marseille Consensus Group: Classification of progressive myoclonus epilepsies and related disorders. *Ann. Neurol.* **28**: 113-116, 1990
- 2) Janz, D. and Christian, W.: Impulsive petit mal. *Dtsch. Z. Nervenheilkd* **176**: 346-386, 1957
- 3) Hallett, M., Chadwick, D. and Marsden, C.D.: Cortical reflex myoclonus. *Neurology* **29**: 1107-1125, 1979
- 4) Berkovic, S.F. and Andermann, F.: The progressive myoclonus epilepsies. *In* Recent advances in epilepsy, No. 3, ed. by Pedley, T.A. and Melderum, B.S. London, Churchill Livingstone. 1986, pp. 157-187
- 5) Marsden, C.D., Hallett, M. and Fahn, S.: The nosology and pathophysiology of myoclonus. *In* Movement disorders, ed. by Marsden, C.D. and Fahn, S. London, Butterworth Scientific. 1981, pp. 196-248
- 6) Rabot, L.: La Myoclonie Épileptique. Thèse, Paris, pp. 1-47, 1899
- 7) Janz, D.: Epilepsy with impulsive petit mal (Juvenile myoclonic epilepsy). *Acta. Neurol. Scand.* **72**: 449-459, 1985
- 8) Berkovic, S.F., Andermann, F., Carpenter, S. and Wolfe, L.S.: Progressive myoclonus epilepsies; specific causes and diagnosis. *N. Engl. J. Med.* **315**: 296-305, 1986
- 9) Naito, H. and Kaji, S.: Clinical picture and type of myoclonus epilepsy with dominant heredity. *Psychiatr. Neurol. Jpn.* **81**: 571-586, 1979 (in Japanese)
- 10) Inazuki, G., Naito, H., Ohama, E., Kawase, Y., Honma, Y., Tokiguchi, S., Hasegawa, S., Tamura, K., Kawai, K., Nagai, H. and Ikuta, F.: A clinical study and neuropathological findings of a familial disease with myoclonus and epilepsy. *Psychiatr. Neurol. Jpn.* **92**: 1-21, 1990 (in Japanese)
- 11) Mahloudji, M. and Pikielny, R.T.: Hereditary essential myoclonus. *Brain* **90**: 669-674, 1967
- 12) Hallett, M., Chadwick, D. and Marsden, C.D.: Ballistic movement overflow myoclonus. *Brain* **100**: 299-312, 1977
- 13) Yasuda, T., Hara, K. and Terao, A.: Essential myoclonus. *Rinsho Noha/Clin. Electroenceph.* **32**: 575-581, 1990 (in Japanese)
- 14) Araki, K., Kono, I., Ueda, Y., Kashima, K. and Shibasaki, H.: A case of familial essential myoclonus-electrophysiological study. *Clin. Neurol.* **31**: 864-868, 1991 (in Japanese)
- 15) Yasuda, T., Terao, A. and Morimoto, K.: A family of benign familial myoclonic epilepsy[abstract]. *Clin. Neurol.* **24**: 1412, 1984 (in Japanese)
- 16) Yasuda, T., Morimoto, K. and Terao, A.: Benign familial myoclonic epilepsy[abstract]. *Epilepsia* **27**: 604, 1986
- 17) Sato, T.: Klinische Beobachtungen von Myoklonusepilepsie. *Psychiatr. Neurol. Jpn.* **30**: 585-591, 1928 (in Japanese)

- 18) Sekino, Y., Imamura, L. and Yamaguchi, T.: Ein Beitrag zur Klinik der sog. Myoklonusepilepsie. *Psychiatr. Neurol. Jpn.* **60**: 617-632, 1958 (in Japanese)
- 19) Tominaga, H., Maekawa, M., Matsuoka, E., Seino, S., Hemmi, M., Kishi, M., Horiguchi, Y., Ohashi, S. and Hashimoto, K.: Clinical and pathological study on a case marked by myoclonus and epileptic seizure. *Iryo* **13**: 444-452, 1959 (in Japanese)
- 20) Tokiguchi, S. and Nagano, Y.: An autopsy case of forme fruste of myoclonus epilepsy. *Neurol. Med. (Tokyo)* **21**: 464-468, 1984 (in Japanese)
- 21) Hartung, E.: Zwei Fälle von Paramyoclonus multiplex mit Epilepsie. *Z. ges. Neurol. Pshiatr.* **56**: 150-153, 1920
- 22) Vogel, F., Häfner, H. und Diebold, K.: Zur Genetic der progressiven Myoklonusepilepsien (Unverricht-Lundborg). *Humangenetik* **1**: 437-475, 1965
- 23) Wakano, M.: A family with heredofamilial tremor associated with epileptic disorders. *Psychiatr. Neurol. Jpn.* **77**: 1-18, 1975 (in Japanese)
- 24) Kudo, J., Kudo, T. and Yamauchi, T.: Seven families of heredofamilial tremor with epilepsy. *Clin. Neurol.* **24**: 1-8, 1984 (in Japanese)
- 25) Yamamoto, K., Osawa, M., Shibata, K., Kobayashi, I., Takemiya, T. and Maruyama, S.: Two brothers of a family with heredofamilial tremor associated with epilepsy; neurophysiological study. *J. Tokyo Women's Med. Coll.* **59**: 585-591, 1989 (in Japanese)
- 26) Wilkins, D.E., Hallet, M. and Erba, G.: Primary generalised epileptic myoclonus; a frequent manifestation of minipolymyoclonus of central origin. *J. Neurol. Neurosurg. Psychiatr.* **48**: 506-516, 1985
- 27) Ikeda, A., Kakigi, R., Funai, N., Neshige, R., Kuroda, Y. and Shibasaki, H.: Cortical tremor; a variant of cortical reflex myoclonus. *Neurology* **40**: 1561-1565, 1990