

Effectiveness of Fluconazole for Pulmonary Aspergilloma and Its Concentration in Lung Tissue

Toshiharu MATSUSHIMA, Makoto KIMURA, Junichi NAKAMURA
and Sadao TOMIZAWA

*Department of Medicine,
Kawasaki Hospital, Kawasaki Medical School,
Okayama 700, Japan*

Accepted for publication on November 21, 1992

ABSTRACT. Fluconazole was administered to two male patients aged 41 and 70 years with pulmonary aspergilloma, the diagnosis of which was based on "fungus balls" on chest X-ray films, isolation of *Aspergillus* from the sputum and positive serum precipitation antibody against *Aspergillus*. The patients received a 100 to 200 mg oral daily dose of fluconazole for six months. The fungus balls shrank and disappeared and *Aspergillus* culture and the serum antibody became negative. No recurrence has been observed during the two years since the end of treatment.

To determine the mechanism by which fluconazole was effective in the treatment of pulmonary aspergilloma, drug levels in the blood and normal and affected lung tissues were determined in 14 patients who received surgery for lung resection. The patients generally received a 200 mg oral daily dose of fluconazole for four days prior to the surgery, during which samples of blood and healthy and affected lung tissues were collected for the determination of fluconazole levels by HPLC. The average fluconazole concentration was 8.2 $\mu\text{g/ml}$ in the blood (14 patients), 9.4 $\mu\text{g/g}$ in healthy lung tissue (10 patients) and 7.7 $\mu\text{g/g}$ in lung lesions (12 patients). Although the results suggested that the drug was well distributed into the blood and lung tissue when administered at an oral dose of 200 mg, the drug levels obtained were found to be far below the growth inhibitory level of fluconazole against *Aspergillus*. Therefore, it may be essential for the future development of antifungal agents and for a better understanding of the pharmacological action of fluconazole to evaluate the mechanism by which the drug exerts its therapeutic effect on aspergilloma at below its growth inhibitory level.

Key words: fluconazole — aspergilloma — serum concentration —
concentration in lung tissue

Fluconazole, a new triazole systemic antifungal agent was used in two patients with pulmonary aspergilloma. Fungus balls rapidly disappeared in one patient and markedly shrank in the other. Negative culturing of *Aspergillus* from their sputum and the improvement of subjective symptoms indicated that fluconazole had therapeutic effects in the treatment of pulmonary aspergilloma. However, the growth inhibitory concentration of fluconazole against *Aspergillus* isolated from their sputum was found to be much higher than the serum drug level in these patients. We hypothesized that the

fluconazole concentration may reach much higher levels in the lung tissue than in serum. To examine this hypothesis, the drug level in the lung tissue was determined in 14 patients who had received lung resection after treatment with fluconazole.

CASES

Two patients with pulmonary aspergilloma received fluconazole for six months.

Case 1 was a 41-year-old man who had experienced right empyema at age 1. This assistant professor of a university had been smoking 20 cigarettes daily for 21 years. He had been well with no subjective complaints until the spring of 1986, when a cavity formation was noted in the right lung during an annual chest survey and he was admitted to our hospital for a complete medical evaluation. His general condition was good and no abnormal findings were noted on physical examination. Chest X-ray films taken on admission (Fig. 1) disclosed a cavity with contents with an upward convex surface in the mediastinal side of the lower lung field. The cavity, which contained several fungus balls of different sizes, was also confirmed on chest CT examination (Fig. 1). *Aspergillus fumigatus* was isolated from the sputum and the serum

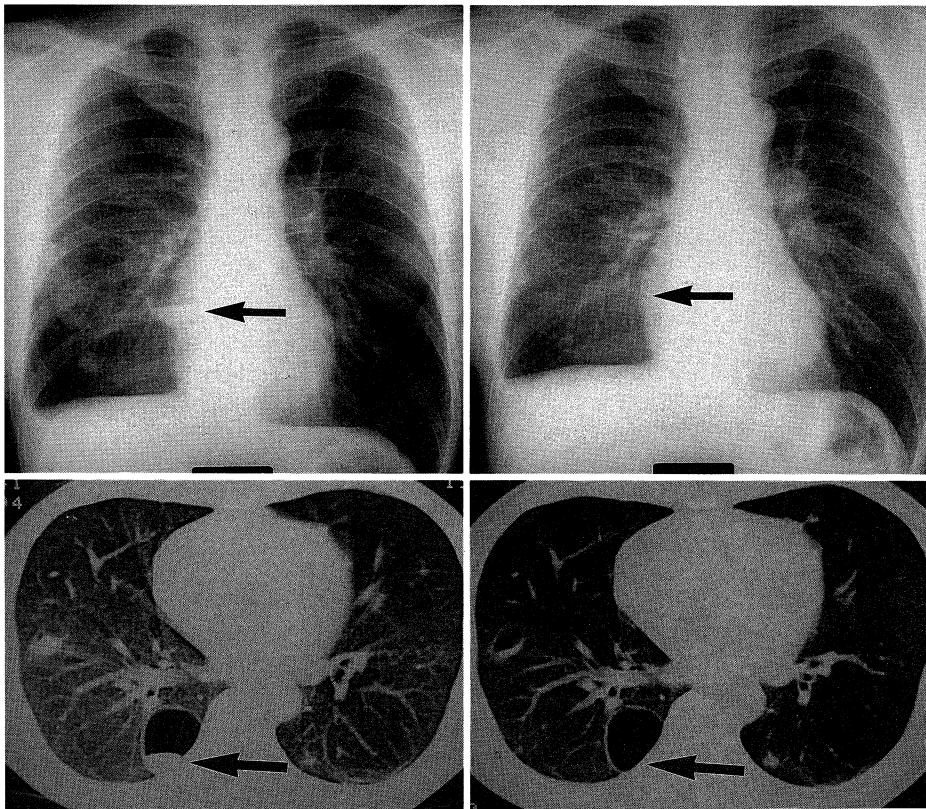


Fig. 1. Chest X-ray films of Case 1 by frontal view (upper) and CT films (lower) before (left side) and after (right side) treatment

anti-*Aspergillus* antibody titer was positive. Fluconazole was orally administered in the morning at an initial daily dose of 100 mg for one week and then at an increased daily dose of 200 mg for six months (Fig. 3). After treatment with fluconazole, *Aspergillus* was not detected in the sputum. The serum antibody titer became negative and *Aspergillus* fungus balls disappeared on X-ray films as shown in Fig. 1. Neither adverse effects nor abnormal laboratory findings were noted during the treatment of six months. The drug was considered to be highly effective in this case. The patient has had no recurrence during the two years since treatment.

Case 2 was a 70-year-old man who had been smoking 30 cigarettes daily for 40 years. He had suffered open tuberculosis five years prior to admission and had received 11-months treatment with antituberculosis drugs. He visited our hospital in August, 1986 because of increasing cough and sputum, followed by a rise in the temperature to over 38°C. He was a small and frail old man, 152 cm in height and 35 kg in weight. There was dullness to percussion with bronchial breath sounds over the bilateral apex to the upper portion of the chest. Chest X-ray films (Fig. 2) showed a profound residual lesions of tuberculosis. Thickening of the bilateral pleurae and the cavity wall suggested

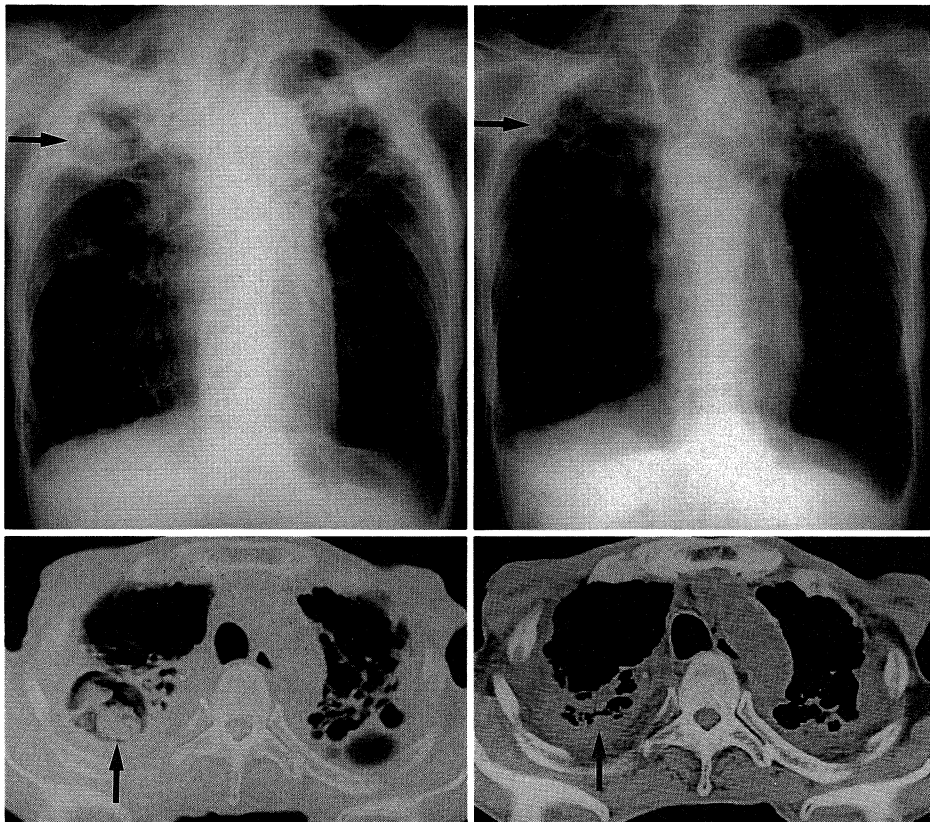


Fig. 2. Chest X-ray films of Case 2 by frontal view (upper) and CT films (lower) before (left side) and after (right side) treatment. Fungus balls indicated by the arrows remarkably shrank after treatment with fluconazole.

fungus ball formation, which was confirmed on CT examination (Fig. 2). *Aspergillus niger* was isolated from the sputum, and his serum antibody titer was also positive. Fluconazole was administered for a total of six months, at an initial daily dose of 200 mg for 6 weeks and then at 100 mg for 20 weeks (Fig. 4). Subjective symptoms improved, sputum cultures became negative and fungus balls disappeared on chest X-ray films (Fig. 2). The drug was found to be highly effective in this patient without causing adverse reactions or abnormal results in laboratory tests. He has been visiting us with no problem for two years since the treatment was ended.

The growth inhibitory concentration of fluconazole was 80 $\mu\text{g/ml}$ or higher against both *Aspergillus fumigatus* in Case 1 and *Aspergillus niger* in Case 2. It has already been proven, however, that 80 $\mu\text{g/ml}$ of fluconazole in the blood cannot be attained with an oral dose of 100 to 200 mg in adults.^{1,2)} Since the drug was therapeutically effective in our patients, we speculated that the fluconazole concentration in the lung tissue may be much higher than that in the circulating blood, being over 80 $\mu\text{g/ml}$. Thus, we determined the fluconazole concentration in the lung tissue as follows.

METHODS FOR DETERMINING FLUCONAZOLE CONCENTRATIONS IN THE BLOOD AND TISSUE

Fourteen patients scheduled for lung resection were selected with their permission for the determination of fluconazole concentrations in lung tissue (Table 1). The patients consisted of 11 men and 3 women with a mean age of 62.4 years (ranging 42 to 75) and a mean body weight of 55.4 kg. The reasons for the operation were pulmonary suppuration with aspergilloma suspected (1 patient), lung abscess (2), atelectasis with lung cancer suspected (1), localized and organized pleuritis (1), and lung cancer (9). Patients with lung cancer represented 64% of the subjects.

Because of its long serum half-life, it is known that oral fluconazole has to be administered repetitively for at least four days before reaching a steady

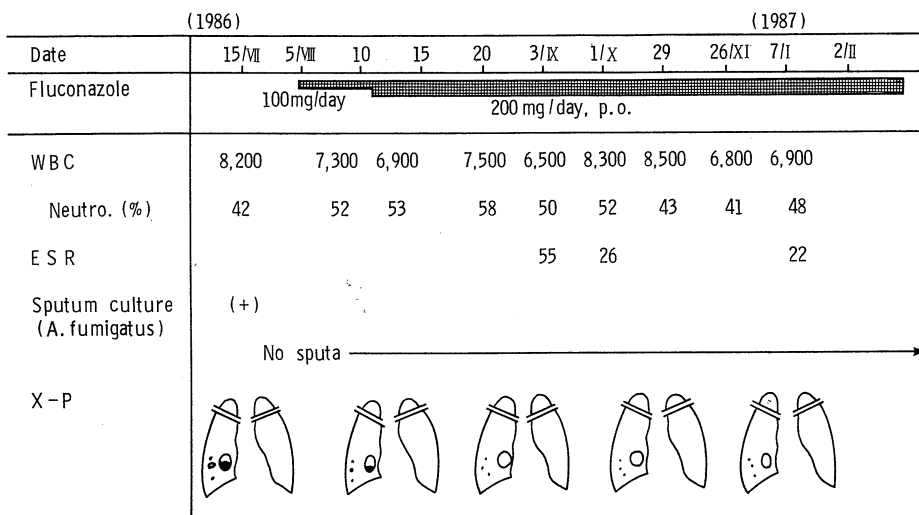


Fig. 3. Clinical course of Case 1 with aspergilloma treated by fluconazole

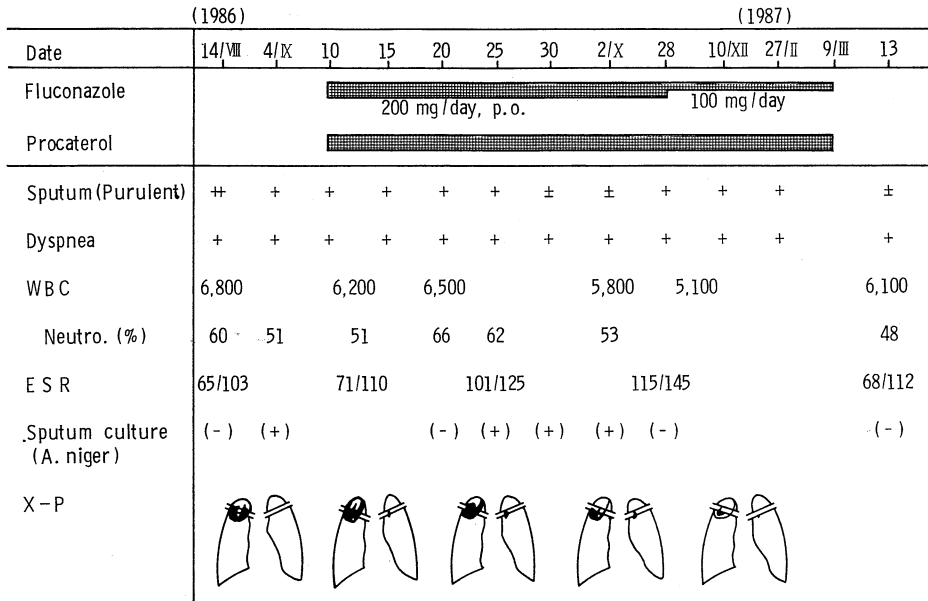


Fig. 4. Clinical course of Case 2 with aspergilloma treated by fluconazole

TABLE 1. Patient characteristics who were determined of fluconazole concentration in the lung tissue

Case No.	Age	Sex	Body Weight	Subject Disease to preoperative	Resect postoperative
1	67	M	58	Aspergilloma	Chronic inflammation
2	68	M	62	Lung cancer(?)	Lung abscess
3	66	M	50	Obstructive pneumonia	Lung abscess
4	42	M	51	Chronic inflammation	Atelectasis (mucoid impaction)
5	56	F	70	Encapsulated pleuritis	Organized pleuritis
6	74	M	52	Lung cancer	Cancer (epidermoid)
7	59	M	50	Lung cancer	" (epidermoid)
8	57	M	51	Lung cancer	" (epidermoid)
9	57	M	60	Lung cancer	" (adeno.)
10	54	M	61	Lung cancer	" (adeno.)
11	75	F	42	Lung cancer	" (adeno.)
12	58	F	64	Lung cancer	" (adeno.)
13	73	M	52	Lung cancer	" (adeno.)
14	67	M	53	Lung cancer	" (adeno.)

state.³⁾ In the present study, therefore, 200 mg of fluconazole once daily was started after supper five days before the operation and was repetitively administered after supper for four days until the night previous to the operation. In Case 5, however, the drug was discontinued on the third day

because of pruritus and mild erythema. In Cases 13 and 14, the drug was administered only twice during three days before the operation.

Three types of specimens were taken from each patient as follows. Blood collected at the lung operation was centrifuged to obtain a serum sample. A tissue block of 1×1×1 cm was cut off from an apparently normal part of the lung immediately after the resection, washed in physiological saline and dried with sterile gauze. A sample block of the lesion was similarly prepared from the affected part of the lung. These specimens were immediately frozen and stored and were thawed directly before determination of the drug level. The tissue blocks were homogenized for the measurement. The fluconazole concentration was measured by high-performance liquid chromatography (HPLC, detector; UV).¹⁾

FLUCONAZOLE CONCENTRATIONS IN THE SERUM AND LUNG TISSUE

Fluconazole levels in the serum and the lung tissues from 14 patients are presented in Table 2. No clear correlation was observed between the time after the last administration of the drug and the serum fluconazole level, although the former widely varied from 11 hours to 43 hours with a mean of 20.8 hours. The serum fluconazole level ranged from 4.8 $\mu\text{g/ml}$ to 15.3 $\mu\text{g/ml}$, average 8.2 $\mu\text{g/ml}$, suggesting that the drug concentration was maintained at a considerably higher level than anticipated. The drug level in the resected lesion ranged from 3.8 $\mu\text{g/g}$ to 15.0 $\mu\text{g/g}$ average 7.7 $\mu\text{g/g}$, which was rather lower than that in the blood or the normal lung tissue. The fluconazole concentration in the lung lesion was much lower than that in the serum in Cases 1, 4 and 10, who had poorly vascularized lesions of chronic atelectasis (Case 4) and scar tissue (Cases 1 and 10). When these cases were excluded from the calculation, the mean drug concentration in the lesions was 8.8 $\mu\text{g/g}$, almost comparable to that in the serum and the normal lung tissue. Although none of the patients in this study had pulmonary aspergilloma, it was surprising that the fluconazole concentration in the lung tissue was far below the anticipated level of 80 $\mu\text{g/ml}$.

DISCUSSION

In pulmonary aspergilloma, *Aspergillus* grows in an abnormal air space in the lung, e.g., in a cavity, cyst or dilated bronchi and forms "a fungus ball".⁴⁾ According to the reports by the Research Committee of Britain Thoracic and Tuberculosis Association, 14% of 544 patients with a mycobacteria negative cavity or cavities had one or more fungus balls⁵⁾ and 20% developed aspergilloma three years after,⁶⁾ suggesting that pulmonary aspergilloma may not be a rare disease. The treatment of this disease has mainly been dependent on surgical resection of the lesion⁷⁾ or local injection of an antifungal agent.⁸⁾ Systemic administration of an antifungal agent has been by infusion except for special cases because only three antifungal agents have been available as effective drugs against deep mycosis;⁹⁾ 5-fluorocytosine (FC), whose anti-*Aspergillus* potency is very weak,¹⁰⁾ and amphotericin B and miconazole, which may produce adverse effects.⁹⁾

Fluconazole, an agent newly developed by Pfizer, exerts a strong

TABLE 2. Fluconazole levels in serum, normal lung tissue, and affected lung tissue after oral administration of 200 mg/day \times 4 days

Case No.	Administered dosis (mg) \times days	Interval* (hour)	Serum (μ g/ml)	Fluconazole Level	
				Lung tissue (μ g/g)	Affected tissue (μ g/g)
1	200 \times 4	15	10.2	15.4	5.6
2	200 \times 4	18	6.1	8.0	6.3
3	200 \times 4	24	15.3	—	14.6
4	200 \times 4	20	9.6	—	3.8
5	200 \times 3	43	4.9	—	6.3
6	200 \times 4	25	4.8	5.7	6.3
7	200 \times 4	11	7.2	6.2	6.0
8	200 \times 4	21	9.6	10.7	10.1
9	200 \times 4	20	6.8	6.4	—
10	200 \times 4	18	7.3	—	3.9
11	200 \times 4	18	9.5	7.3	—
12	200 \times 4	19	12.2	19.7	15.0
13	200 \times 2	18	6.5	7.8	7.9
14	200 \times 2	21	5.0	6.3	6.9
average	200 \times 3.6	20.8	8.2	9.4	7.7

*Time interval from last take of drug to resection

antifungal effect against a wide spectrum of fungi including *Aspergillus*,¹¹⁾ rarely develops adverse reactions¹²⁾ and can be used orally.¹²⁾ These properties seem to make this drug quite suitable for the treatment of chronic deep fungal infections including pulmonary aspergilloma. We used this drug in two patients with pulmonary aspergilloma for six months and noted excellent effectiveness of the drug as shown by disappearance of fungus balls, negative sputum cultures and a negative serum antibody titer. A similar drastic disappearance of fungus balls was also noted by Yoneda.¹³⁾ Joint research performed in Japan¹⁴⁾ also showed fluconazole to be therapeutically effective in 14 of 28 patients (50%) with aspergilloma, indicating its extremely high effectiveness. Therefore, this drug is considered to be quite appropriate for the treatment of pulmonary aspergilloma.

On the other hand, although fluconazole was highly effective in our two patients, its growth inhibitory concentration against *Aspergillus* species isolated from these patients was over 80 μ g/ml, much higher than the serum drug concentration.

We speculated that the fluconazole concentration in the lung tissue might be higher than that in the serum and that it would exceed the growth inhibitory level against *Aspergillus*. To examine our hypothesis, we decided to determine the drug level in lung tissue using samples collected from resected lung specimens. The results showed that the fluconazole concentration was similar in both normal and affected lung tissues, and that the normal lung tissue level was slightly higher and the affected lung tissue level was slightly lower in comparison to the serum level. The fluconazole concentration in the lung tissue was far below the growth inhibitory level against *Aspergillus*, providing no explanation for the efficacy of the drug against aspergilloma.

As with our two patients, many researchers have reported the efficacy of fluconazole in patients with pulmonary aspergilloma.¹⁴⁾ However, the traditional concept for the mechanism of action of antimicrobial agents cannot explain the efficacy of fluconazole, which seems to suppress the growth of *Aspergillus* at a level below its growth inhibitory concentration. It can be elucidated this mechanism, new aspects of the antifungal effect of fluconazole would become clear, and it might be helpful for further development of other systemic antifungal drugs.

SUMMARY

Two patients with pulmonary aspergilloma received a 100 to 200 mg daily dose of fluconazole orally for six months. After six months of treatment, fungus balls shrank or disappeared, sputum cultures became negative and the serum antibody titer decreased to the negative level. To determine the anti-aspergilloma efficacy of the drug, the fluconazole concentration in lung tissue was determined. The results showed that the fluconazole levels in the normal and affected lung tissues were comparable to that in the serum; i.e., 9.4 $\mu\text{g/g}$, 7.7 $\mu\text{g/g}$ and 8.2 $\mu\text{g/ml}$ respectively. However, these levels were far below the growth inhibitory level of the drug against *Aspergillus*. Therefore, it may be meaningful to elucidate the mechanism by which fluconazole exerts effective antifungal action at a level below its growth inhibitory concentration.

REFERENCES

- 1) Shiba, T. and Saito, A.: Pharmacokinetic evaluation of fluconazole in healthy volunteers. *Jpn. J. Antibiot.* **42**: 17-30, 1989
- 2) Dupont, B. and Drouhet, E.: Fluconazole for the treatment of fungal diseases in immunosuppressed patients. *Ann. N.Y. Acad. Sci.* **544**: 564-570, 1988
- 3) Foulds, G., Wajsznck, C., Weidler, D.J., Garg, D.J. and Gibson, P.: Steady state parenteral kinetics of fluconazole in man. *Ann. N.Y. Acad. Sci.* **544**: 427-430, 1988
- 4) Levin, E.J.: Pulmonary intracavity fungus ball. *Radiology* **66**: 9-16, 1956
- 5) Research Committee of the British Tuberculosis Association: *Aspergillus* in persistent lung cavities after tuberculosis. *Tubercle* **49**: 1-11, 1968
- 6) Research Committee of the British Thoracic and Tuberculosis Association: Aspergilloma and residual tuberculosis cavities — The results of a resurvey. *Tubercle* **51**: 227-245, 1970
- 7) Kilman, J.W. and Ahn, C.: Surgery for pulmonary aspergillosis. *J. Thorac. Cardiovasc. Surg.* **57**: 642-647, 1969
- 8) Hargis J.R., Bone, R.C., Steward, J., Rector, N. and Hiller, F.C.: Intracavity amphotericin B in the treatment of symptomatic pulmonary aspergilloma. *Am. J. Med.* **68**: 389-394, 1980
- 9) Medoff, G. and Kobayashi, G.: Strategies in the treatment of systemic fungal infections. *N. Engl. J. Med.* **302**: 145-155, 1980
- 10) Bennet J.: Flucytosine. *Ann. Intern. Med.* **86**: 319-322, 1977
- 11) Odds, F.C., Cheesman, S.L. and Abott, A.B.: Antifungal effects of fluconazole (UK-49, 858), a new triazole antifungal, in vitro. *J. Antimicrob. Chemother.* **18**: 473-478, 1986
- 12) Tachibana, M., Noguchi, Y. and Monro, A.M.: Toxicology of fluconazole in experimental animals. *In* Recent Trends in the Discovery, Development and Evaluation of Antifungal Agents, ed. by Fromtling, R.A. Prous Science Publishers. 1987, pp. 93-102
- 13) Yoneda, R.: A clinical study of fluconazole in pulmonary aspergillosis. *Jpn. J. Antibiot.* **42**: 40-46, 1989
- 14) Ikemoto, H., Watanabe, K., Mori, T. and 33 institutes.: Clinical study of fluconazole in deep-seated fungal infections. *Jpn. J. Antibiot.* **42**: 63-116, 1989