

Case Study of Human Infection with *Diplogonoporus grandis* (Cestoda: Diphyllbothriidae) Found in Okayama Prefecture, Japan

Ryo HATSUSHIKA, Tetsuya OKINO and Seiichi MATSUDA*

Department of Parasitology,
Kawasaki Medical School, Kurashiki 701-01, Japan

* Mabi Central Hospital,
Mabi-Cho, Kibi-Gun, Okayama 710-13, Japan

Accepted for publication on October 11, 1994

ABSTRACT. The second case of human diplogonoporiasis found in Okayama Prefecture, Japan is reported. The patient was a 65-year-old male living in Mabi-Cho, Kibi-Gun in Okayama. On February 27th 1993, the patient had found and evacuated spontaneously a fragmented strobila without scolex of about 170 cm in length and 12.5 mm in maximum width, then he brought to Mabi Central Hospital a flat parasite. The patient had customary been eating raw meats of shark as well as marine fishes such as yellow-tail, horse-mackerel and cuttlefish. The fragmented strobila was identified as *Diplogonoporus grandis* (Blanchard, 1894) Lühe, 1899, based on morphological characteristics of two sets of genital organs in all proglottids of strobila, eggs and serial (transverse and sagittal) sections of proglottids.

Key words: human diplogonoporiasis — *Diplogonoporus grandis* —
Diphyllbothriidae — Cestoda — Okayama Prefecture

Human diplogonoporiasis caused by infection of diplogonadic tapeworm, *Diplogonoporus grandis* (Blanchard, 1894) Lühe, 1899, has been peculiar parasitic disease in Japan because no human cases have been reported outside Japan. Although reliable lifecycle and routes of human infection with this species are extremely unknown, the most patient of *D. grandis* infection in the past had been accustomed to consume raw marine fishes such as salmon, trout, sardine, yellow-tail, horse-mackerel, bonito, etc in the form of Sashimi, known as Japan's delicacy.

The first human case of *D. grandis* infection in Japan was reported by Ijima and Kurimoto (1894)¹⁾ of a 26-year-old male residing in Nagasaki Prefecture, Kyushu. Thereafter, cases of diplogonoporiasis have gradually increased in number. Very recently a total of 183 authentic cases before 1992 have briefly been summarized by Suzuki *et al* (1993).²⁾

A majority of 183 patients are distributed in coastal areas west of Kanto District, mainly in Kochi, Shizuoka, Tottori and Nagasaki Prefectures in the order of appearing frequency. The human diplogonoporiasis in Okayama Prefecture have thus far been limited to only one case (Inatomi and Iwata, 1965).³⁾ The present authors wish to report a new case of the infection with *D.*

grandis found in Okayama Prefecture together with some photomicrographs of the worm observed by light and scanning electron microscopy.

CASE NOTE

The Patient (KK) was a 65-year-old male, a resident of Mabi-Cho, Kibi-Gun in Okayama. On the morning of February 27th 1993, the patient noticed the presence of a string-like milk white strange body extruding from his anal canal as bowel movement began. Hence he grasped the body with toilet tissue, and pulled it out. He immediately visited Mabi Central Hospital carrying the removed body with him. The most striking symptom of the patient was pruritus, felt as itching at the entire circumference of his anus for the last 3 days. He had no diarrhea in the last several years. The findings of blood examination revealed as follows: erythrocyte count 587×10^4 , leucocyte 5,200, hemoglobin 15.0 g/dl, hematocrit 44.7% and no eosinophilia. On stool examinations the large number of typical diphyllbothriid eggs were found. On April 21th 1993, the patient was treated with Bithionol followed by magnesium sulfate and resulted to have evacuation of a short strobila about 130 cm in length. This specimen, however, was not examinable because of the strobila has already been disintegrated when the specimen arrived at our laboratory. There was no trace of the eggs from the patient's feces after the treatment.

DESCRIPTION OF THE WORM

The detailed morphological study was made on the strobila and the eggs. The proglottids were observed in whole mount preparation stained with Semichon's carmine. Some proglottids were embedded in paraffin and serially sectioned at 10 μm in transverse and sagittal directions, and stained with Trichrome stain solution. The eggs examined were removed from uterine ducts of proglottids and egg-shell surfaces were studied with a Hitachi S-570 scanning electron microscope after prepared by the ordinary techniques.

Measurements of each part of the strobila and the eggs are shown in Table 1. The fragmented strobila without scolex measured about 170 cm in length and 12.5 mm in maximum width (Fig 1). The proglottids were much wider than length and each proglottid had two sets of genital organs (Fig 2, 3).

All parts of cuticular layer of the proglottid were almost peeled off with unknown reason. The proglottids measured 0.7 to 1.2 mm in length and about 1.0 mm in thickness. The distance between two genitalia was 2.5 to 3.6 mm which occupied 1/3 of full width of the proglottid (Fig 2, 3).

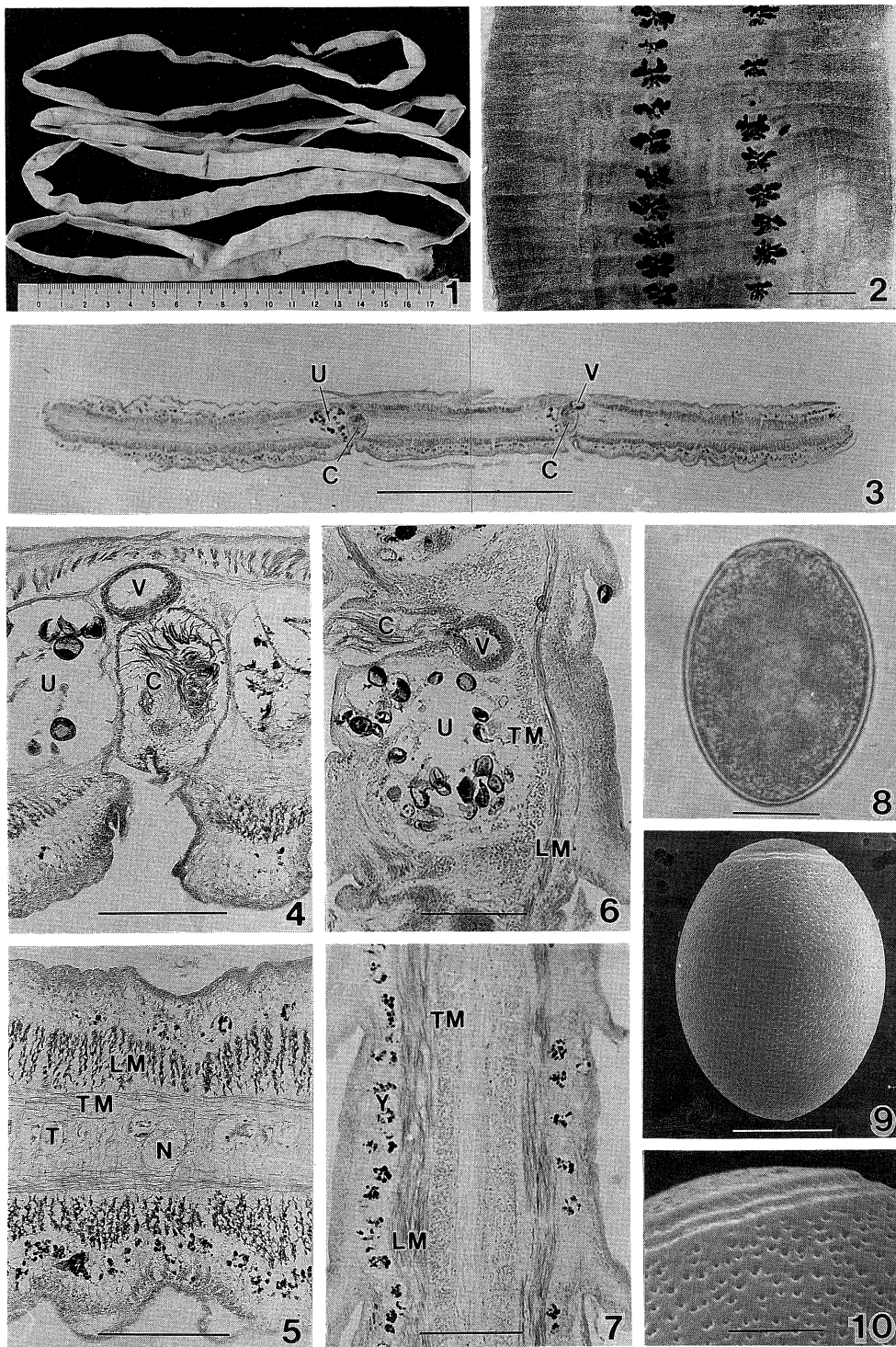
In transverse sections of the proglottids, the cortical zone situated in the ventral and dorsal parts was 230 to 390 μm thick, in which there longitudinal muscle fibers and yolk glands existed. A layer of longitudinal muscle was relatively thick, measuring 70 to 140 μm thick and a layer of transverse muscle was 40 to 70 μm in thickness (Fig 3, 5). The yolk glands seemed to be less developed in dorsal side than those in ventral side. Medullary zone was 100 to 250 μm in thickness examined in transverse sections. The testes were arranged in a single layer occupying in the medullary zone, dorsal region (Fig 5). The testes were poorly developed, measuring 30 to 130 μm in the sagittal

TABLE 1. Morphological data of *D. grandis* found in the patient from Okayama, 1993

Strobila	
length	170 cm
maximum width	12.5 mm
Proglottid	
length	0.7-1.2 mm
thickness	1.0 mm
Distance of two genitalia	2.5-3.6 mm
Cirrus-sac	
length	350 μ m
width	210 μ m
wall thickness	30 μ m
Vesicular seminalis	
length	200 μ m
width	150 μ m
wall thickness	40 μ m
Arrangement of testis	single layer
Diameter of testis	30-70 \times 50-130 μ m
No. of testis in	
transverse section	about 80
sagittal section	about 12
Thickness of muscle layer	
longitudinal	70-140 μ m
transverse	40- 70 μ m
Diameter of nerve trunk	70- 80 μ m
Thickness of	
cortical parenchyma	230-390 μ m
medurally parenchyma	100-250 μ m
Size of eggs	
length	59.7-72.9 μ m (av. 65.3)
maximum width	45.1-51.4 μ m (av. 48.2)
Thickness of egg shells	1.7- 2.8 μ m (av. 2.3)

sections. Two median longitudinal nerve trunks lied in the medullary zone, one on each on lateral side, about halfway between genital opening and lateral margin of the proglottid in the transverse sections. The nerve trunk measured 70 to 80 μ m in diameter (Fig 5).

The cirrus-sac was pyriform and dorsally extends from genital opening, measuring about 350 μ m dorso-ventrally and 210 μ m in diameter in the sagittal sections. The cirrus-sac wall was about 30 μ m in thickness (Fig 4, 6). The seminal vesicle was oval antero-posteriorly and situated just behind the cirrus-sac, which was directly connected each other dorso-posteriorly in the sagittal sections (Fig 6). The seminal vesicle measured about 200 μ m dorso-ventrally and 150 μ m in diameter in the sagittal sections. The seminal



- Fig 1. Whole figure of strobila obtained
 Fig 2. Proglottids from posterior part of strobila stained with Semichon's carmine (Scale=3.0 mm)
 Fig 3. Transverse section of proglottid passing through the level of the genital field (Scale=3.0 mm)
 Fig 4. Portion of transverse section passing through a genital pore (Scale=30 μ m)
 Fig 5. Portion of transverse section showing details of lateral field (Scale=30 μ m)
 Fig 6. Sagittal section passing through the genital pore (Scale=30 μ m)
 Fig 7. Sagittal section passing through the lateral field (Scale=30 μ m)
 Fig 8. An egg (Scale=20 μ m)
 Fig 9. SEM picture of egg-shell surface (Scale=20 μ m)
 Fig 10. High mag SEM picture of egg-shell surface showing pits and opercular suture (Scale=6 μ m)

C: cirrus-sac, LM: longitudinal muscle layer, N: nerve trunk, T: testis, TM: transverse muscle, layer, U: uterus, V: vesicular seminalis, Y: yolk gland

vesicle wall measured about 40 μ m in thickness.

The oval eggs without apical knobs, measured 59.7 to 72.9 μ m (av 65.3) in length and 45.1 to 51.4 μ m (av 48.2) in maximum width (Fig 8). The egg-shells were 1.7 to 2.8 μ m (av 2.3) in thickness, having scattered deep pits on the surfaces (Fig 8-10).

DISCUSSION

It is accepted that the tapeworm with two sets of genital organs in each proglottid can generally be identified as Genus *Diplogonoporus* of Family Diphyllbothriidae. Morphological features of *D. grandis* (Blanchard, 1894) Lühe, 1899, resembled very closely to those of *Diplogonoporus balaenopterae* Lönnberg, 1892, which is an intestinal parasite of several kinds of whales in Genus *Balaenoptera*. At present, both *D. grandis* and *D. balaenopterae* are considered as same species.⁴⁾

The patients infected with *D. grandis* have never been reported in outside Japan. The first case of human infection with *D. grandis* in Japan was reported by Ijima and Kurimoto¹⁾ in 1894, and recently by Suzuki *et al* (1993)²⁾ who summarized 183 cases to 1992. Thereafter, 26 human cases were then reported by Nakamura *et al* (1993),⁵⁾ Harada *et al* (1993),⁶⁾ Terada *et al* (1993),⁷⁾ Kawada *et al* (1994),⁸⁾ Akao *et al* (1994)⁹⁾ and Maejima *et al* (1994).¹⁰⁾ Hence, a total number of the patients of *D. grandis* infection thus far is 210 including the present case.

Although the human cases of *D. grandis* infection are known widely in the coastal areas but mostly west of Kanto District, prefectural distribution of those 210 patients are: 56 in Shizuoka; 40 in Kochi; 22 in Tottori; 16 in Nagasaki; 8 in Shimane; 7 in Fukuoka; 5 each in Chiba, Kanagawa and Osaka; 4 each in Ehime, Kumamoto and Kagoshima; 3 each in Aomori, Ibaragi and Hiroshima; 2 each in Saitama, Tokyo, Nagano, Mie, Wakayama, Okayama, Yamaguchi, Oita and Miyazaki; and one each in Fukushima, Tochigi, Aichi, Toyama, Kyoto, Hyogo and Saga.

According to Inatomi and Iwata (1965),³⁾ which was first report in Okayama, the patient was a 54-year-old male living in Jingo-Cho, Atetsu-Gun in Okayama. The specimen revealed that the strobila without scolex is about 20 cm in length and 18 mm in maximum width, with two sets of genital organs in the proglottid. Their report also predicated that the *D. grandis* infection

may occur among inland inhabitants as well as coastal residents in near future. Indeed, Nakamura *et al* (1993),⁵⁾ have recently reported two cases of human diplogonoporiasis from Nagano Prefecture situated in the mountain area.

It is conceivable that *D. grandis* is primarily intestinal parasite of baleen whales, and human infection of this tapeworm is thought to be an accidental event. Therefore, the tapeworms of the Genus *Diplogonoporus* infected into human body tend to be evacuated spontaneously, chiefly because this parasite has low susceptibility to human intestines.

The life-cycle of *D. grandis* is not well-defined except for the experimental study by Kamo *et al* (1972,¹¹⁾ 1973¹²⁾). They demonstrated that when *D. grandis* eggs were incubated in sea water at 25 to 27 °C, the coracidia matured 4 to 5 days after incubation and began to hatch. They also found that the hatched coracidia had strong affinity to two kinds of marine copepods, *Oithona nana* and *Labidocera japonica*, which were common in the sea surrounding Japan. According to their study, within 3 hrs after feeding the liberated coracidia encroached on the body cavity passing through the intestinal wall of copepods. The larvae developed into full ripened procercoids in 9 to 10 days. Other studies related to the life-cycle including the 2nd intermediate hosts and source of human infection are quite unknown.

Judging from eating habits of the most patients in the past *D. grandis* infection, a majority are exceedingly fond of "Sashimi", and they often eat many kinds of marine fishes and shellfishes, viz, sardine (*Sardinops melanosticta*), big-eye sardine (*Etrumeus micropus*), anchovy (*Engraulis japonica*), horse mackerel (*Trachurus japonicus*), common Japanese mackerel (*Scomber japonicus*), spotted mackerel (*Scomber tapeinocephalus*), bonito (*Katsuwonus pelamis*), yellow-tail (*Seriola quinqueradiata*), dolphin (*Coryphaena hippura*), tuna (*Thunnus thynnus*) and sagittated calamary (*Todarodes pacificus*). Thus many marine fishes are presently suspected as possible sources of human *D. grandis* infection.

Therefore, it is strongly assumed that the present case as well might be one infected by ingestion of raw meats of shark or marine fishes.

REFERENCES

- 1) Ijima I, Kurimoto T: On a new human tape-worm (*Bothriocephalus* sp.). J Coll Sci Imp Univ Tokyo 6: 372-385, 1894
- 2) Suzuki N, Imamura K, Kumazawa H: Diplogonoporiasis in Kochi Prefecture between 1991-92. Jpn J Parasitol 42: 123-127, 1993 (in Japanese with English summary)
- 3) Inatomi S, Iwata S: On a case of parasitism of *Diplogonoporus grandis*. Jpn J Parasitol 14: 642, 1965 (in Japanese)
- 4) Iwata S: *Diplogonoporus grandis* (Blanchard, 1894) is the synonyms of *D. balaenopterae* Lönnberg, 1892. Proc Jap Soc Syst Zool 3: 20-24, 1967 (in Japanese with English summary)
- 5) Nakamura N, Nakayama J, Shimazu T, Kojima K, Uchikawa K: First two cases of diplogonoporiasis grandis from Nagano Prefecture, Japan. Jpn J Parasitol 42: 434-437, 1993
- 6) Harada K, Mitsuyama K, Nishiyama T, Ban S, Shigemori H, Minetoma T, Sasaki A, Toyonaga J, Yoshida H, Tanikawa K, Takao Y, Fukuma T: A case of two individuals infection of *Diplogonoporus grandis* in Kurume City, Kyushu. Clinical Parasitol 4: 119-123, 1993 (in Japanese)
- 7) Terada M, Kino H, Ishii A, Sano M: Twelve cases of *Diplogonoporus grandis* infection in Shizuoka Prefecture, Japan. Clinical Parasitol 4: 124-126, 1993 (in Japanese)

- 8) Kawada K, Kawamura N, Shiba Y, Shigematsu T, Kanai T, Mikami Y, Tanaka K, Eguchi T, Nakamura T: Additional 4 cases of diplogonoporiasis in Shizuoka Prefecture. *Jpn J Parasitol* **43**: 72, 1994 (in Japanese)
- 9) Akao S, Takahashi A, Mikami S, Mikami F, Imamura K, Kudo Y: Four human cases of diplogonoporiasis. *Jpn J Parasitol* **43** (Suppl): 122, 1994 (in Japanese)
- 10) Maejima J, Yazaki S, Fukumoto S, Tanihata T, Wang H, Hirai K: Three cases of diplogonoporiasis in Tottori Prefecture. *Jpn J Parasitol* **43** (Suppl): 134, 1994 (in Japanese)
- 11) Kamo H, Iwata S, Hatsushika R, Maejima J: Experimental studies on the life-cycle of *Diplogonoporus grandis*. I. Embryonation and hatching of the egg. *Jpn J Parasitol* **21**: 59-69, 1972 (in Japanese with English summary)
- 12) Kamo H, Iwata S, Hatsushika R, Maejima J: Experimental studies on the life-cycle of *Diplogonoporus grandis*. II. Experimental infection of marine copepods with coracidia. *Jpn J Parasitol* **22**: 79-89, 1973 (in Japanese with English summary)