

**A Case Study of Human Otomyiasis Caused
by *Parasarcophaga similis* (Meade, 1876)
(Diptera : Sarcophagidae) Found in Hiroshima, Japan**

Ryo HATSUSHIKA, Hiroshi USHIROGAWA and Yuzuru IWANAGA*

*Department of Parasitology, Kawasaki Medical School,
Kurashiki 701-0192, Japan*

**Department of Immunology and Parasitology,
Hiroshima University School of Medicine, Hiroshima 734-8551, Japan*

Accepted for publication on August 19, 2002

ABSTRACT. A rare human case of auditory meatus infestation with dipterous larvae found in a 74-year-old male residing in Hiroshima City, Japan is reported. On August 7, 2001, the patient consulted a local physician, complaining of auditory discomfort and aural discharge from his left ear, and acute otitis media was suspected. Otological examination revealed three dipterous larvae in the patient's left external auditory meatus. The removed larvae measured about 9.5 mm in length and 2.0 mm in maximum diameter with 12 visible segments on the body surface. By insectological observation, the specimens were identified as the 3rd instar larva of *Parasarcophaga similis* (Meade, 1876), belonging to the family Sarcophagidae, based on morphological characteristics of the cephalopharyngeal sclerite and anterior and posterior spiracles.

To the best of our knowledge, the present report is the 3rd case of human otomyiasis caused by *P. similis* in Japan. The details and some bibliographical data are reported.

Key words : human otomyiasis — *Parasarcophaga similis* — 3rd instar larva — Sarcophagidae — Diptera

Myiasis is the term used for the invasion of living, necrotic, or dead animal or human tissues by the larvae (also known as maggots) of various dipterous (two-winged) flies.¹⁾ Although the houseflies around residences have no doubt been decreasing in recent years in Japan, they are still the most important insects affecting human hygiene. The adult fly conveys various kinds of enteric pathogens, such as microbial agents, some protozoan cysts and helminthic ova attaching to their body surface and legs, and freely spreads pathogenic organisms in and out of the house.

The larvae of several fly species, on the other hand, are frequently found in the human body, namely in the digestive organs (stomach, intestine and rectum), otorhinolaryngeal organs (internal and external ear canals, nose, pharynx, mouth and accessory sinuses), urogenital organs (in urine and the urogenitals), ophthalmic organs (the eyelid) as well as in or on the skin. Some of the more important dipterous flies capable of producing human myiasis belong chiefly to the families Muscidae, Calliphoridae, Sarcophagidae

and Cuterebridae.

In this paper, a rare human case of otomyiasis found in Hiroshima City, Japan is described together with some photomicrographs of the agential larva and bibliographical consideration.

CASE NOTE

The patient (S. M.) was a 74-year-old male residing in Hiroshima City, Japan. He fell into a state of cerebral apoplexy three years ago, and has been suffering from motor disturbances of his extremities ever since. He had resided in Hiroshima Prefecture almost all his life and had never left the country. On August 7, 2001, the patient presented to the Iwamoto Internal Clinic in Hiroshima City, complaining of auditory discomfort and marked aural discharge from his left ear. He was then suspected of having acute otitis media.

On examination of the patient's left ear canal with an ear speculum, three moving foreign bodies which looked somewhat like small maggots were found in the inner part of the external auditory canal. The foreign bodies were carefully removed with a forceps. On gross inspection, they were confirmed from their external appearance, as larvae of certain dipterous species. The aural discharge and auditory discomfort of the patient disappeared immediately after they were removed, and his hearing acuity has completely recovered.

Superficial examination of the left ear canal of the patient revealed simple erosive lesions on the lateral surface of the external auditory canal, and pooling of mucoid aural discharge in this area. However, no serious damage caused by the infesting larvae was recognized in middle or inner ears. The aural lesions completely healed within three weeks with ordinary antiseptic treatment after removal of the infesting larvae. Although trifling damage was seen on the tympanic membrane of the patient's left ear, it was not known whether the damage had been principally caused by the infesting larvae. To the best of our knowledge, this is the 32nd reported case of human otomyiasis in Japan since 1946, as shown in Table 1.²⁻¹⁶⁾

MORPHOLOGICAL ASPECTS OF THE LARVAE

The three dipterous larvae removed from the patient were fixed in 70% alcohol and one was sent to our school for taxonomical judgment by the laboratory of the Hiroshima Medical Association. The three larvae were almost equal in size, and the one examined measured about 9.5 mm in length and 2.0 mm in maximum diameter. On dissecting binocular microscopic examination, the larva was milk-white in color and somewhat cylindrical in form, with 12 circular ring-shaped visible segments (one head segment, three thoracic segments and eight abdominal segments) on the external surface of the body. The larva had a broad truncated or rounded posterior and a narrow anterior with hook-like processes, and anterior spiracles were observed on both sides of the 2nd segment of the larva. A cephalopharyngeal sclerite located in the cephalothoracic region was faintly seen through the translucent body of the larva (Fig 1). On the distal end of the terminal segment, two sets of posterior spiracles were recognized in

TABLE 1. Human cases of otomyiasis reported in Japan (since 1946)

Cases	Patients			Infested fly larvae			Authors (year)
	ages	sexes	residences	instars (ages)	numbers	species	
1	8	M	Tokyo	1	29	<i>Musca domestica</i>	Kusaka (1952) ²⁾
2	2	M	Fukui	?	?	?	Ijima (1953) ³⁾
3	31	F	?	?	?	?	Fujiwara (1954) ⁴⁾
4	74	F	Mie	3	11	<i>Phaenicia sericata</i>	Yoshii et Ohkawa (1957) ⁵⁾
5	newborn infant	F	Tokyo	1-2	3	<i>Parasarcophaga harpax</i>	Kaneko et al (1968) ⁶⁾
6	8	M	Tokyo	?	many	?	Kawashima (1971) ⁷⁾
7	newborn infant	F	Tokyo	2	2	<i>Boettcherisca peregrina</i>	Yagisawa et al (1975) ⁸⁾
8	9	F	Mie	?	?	<i>Drosophila melanogaster</i>	Ohkawa (1979) ⁹⁾
9	9	M	Mie	?	?	<i>Musca vicina</i>	
10	8	F	Mie	?	?	<i>Musca vicina</i>	
11	8	M	Mie	?	?	<i>Musca vicina</i>	
12	9	M	Mie	?	?	<i>Musca vicina</i>	
13	35	F	Mie	?	?	<i>Musca vicina</i>	
14	26	F	Mie	?	?	<i>Musca vicina</i>	
15	?	?	Mie	?	?	<i>Musca vicina</i>	
16	74	F	Mie	?	11	<i>Phaenicia sericata</i>	
17	25	F	Mie	?	1	<i>Phaenicia sericata</i>	
18	62	F	Mie	?	?	<i>Phaenicia cuprina</i>	
19	41	F	Mie	?	?	<i>Phaenicia cuprina</i>	
20	58	M	Mie	?	?	<i>Sarcophaga peregrina</i>	
21	7	M	Mie	?	3	<i>Sarcophaga peregrina</i>	
22	7	M	Mie	?	?	<i>Sarcophaga peregrina</i>	
23	newborn infant	?	Tokyo	3	?	<i>Boettcherisca peregrina</i>	Koga et al (1985) ¹⁰⁾
24	newborn infant	?	?	?	?	?	Ohyama (1986) ¹¹⁾
25	50	F	Okayama	1	7	<i>Parasarcophaga similis</i>	Hatsushika et al (1988) ¹²⁾
26	newborn infant	F	Tochigi	2	30	<i>Sarcophaga peregrina</i>	Chigusa et al (1994) ¹³⁾ Sasaki et al (1994) ¹⁴⁾
27	6	F	Ibaraki	2	6	<i>Sarcophaga similis</i>	
28	68	F	Oita	2	many	<i>Boettcherisca peregrina</i>	Yoneda et al (1998) ¹⁵⁾
29	newborn infant	F	Fukuoka	2	?	<i>Boettcherisca peregrina</i>	
30	77	F	Fukuoka	2	many	<i>Lucilia sericata</i>	Chigusa et al (1999) ¹⁶⁾
31	81	F	Tochigi	?	?	<i>Lucilia sericata</i>	
32	74	M	Hiroshima	3	3	<i>Parasarcophaga similis</i>	Present report

M=male, F=female, *M. vicina*=*M. domestica*, *S. peregrina*=*B. peregrina*, *S. similis*=*P. similis*, *L. sericata*=*P. sericata*

the concavity of the surface.

Prior to morphological examination, the anterior portion (including the

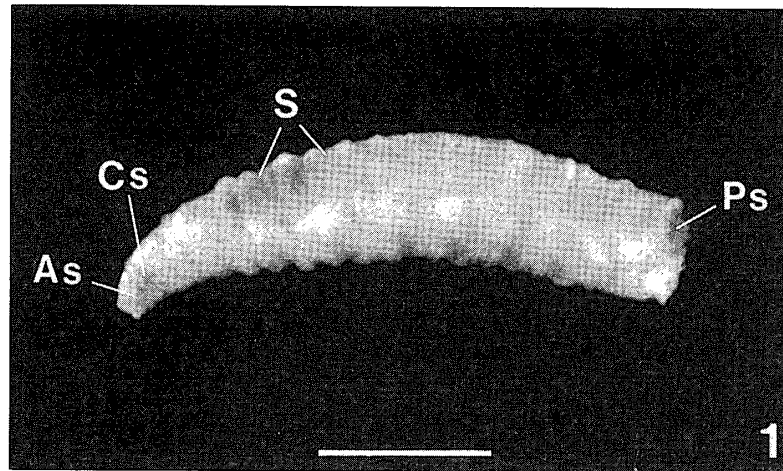


Fig 1. Whole body of the dipterous larva removed from the left external auditory meatus of the patient, fixed in 70% alcohol (Scale bar=3.0 mm).

As : anterior spiracle, Cs : cephalopharyngeal sclerite, Ps : posterior spiracle, S : segment

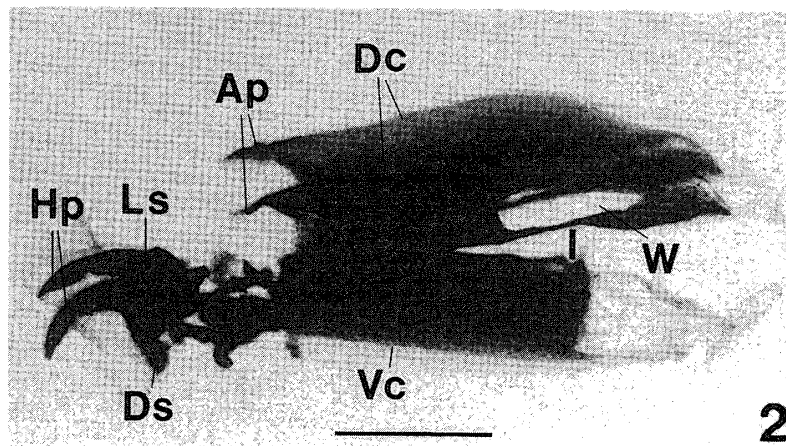


Fig 2. A cephalopharyngeal sclerite situated in the cephalothoracic region of the larva, lateral view (Scale bar=0.3 mm).

Ap : anterodorsal process, Dc : dorsal cornua, Ds : dental sclerite, Hp : hook part, I : incision, Ls : labial sclerite, Vc : ventral cornua, W : window

1st and 2nd segments) and the posterior portion of the most caudal segment of the larva were cut away, and the separated materials were boiled for 20 min in a 1% aqueous solution of NaOH. The isolated cephalopharyngeal sclerite and anterior and posterior spiracles were dehydrated through a graded series of ethanol, mounted in Canada balsam, and studied in detail with a light microscope.

The cephalopharyngeal sclerite was dark brown in color, and measured about 1.1 mm in length and 0.5 mm in dorsoventral height (Fig 2). The anterodorsal process of the dorsal cornua was sharply pointed forward. The hook part of the labial sclerite was relatively long and slender in form and gently pointed downward. The ventral cornua was apparently longer than half the length of the dorsal cornua in its total length. The incision between the dorsal and ventral cornuae was remarkably deep, and the

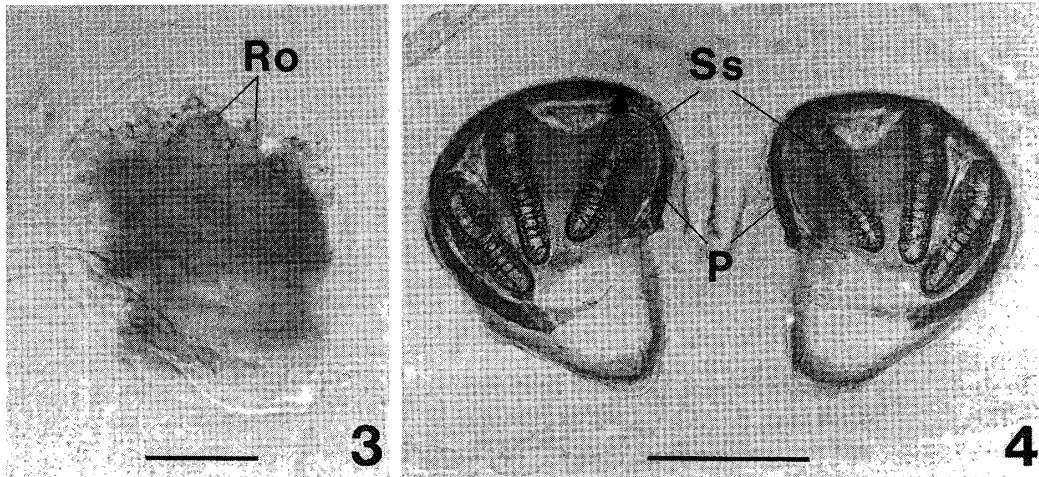


Fig 3. Photomicrograph showing an anterior spiracle (left side) located on both sides of the 2nd segment of the larva (Scale bar=0.1 mm).

Ro : respiratory opening

Fig 4. Photomicrograph of two posterior spiracles located on the terminal segment of the larva, caudal view (Scale bar=0.2 mm).

P : peritreme, Ss : spiracular slit

TABLE 2. Human cases of infestation with *Parasarcophaga similis* larvae reported in Japan

Cases	Patients			Infested larvae			Authors (year)
	ages	sexes	residences	locations	instars (ages)	numbers	
1	77	F	Ibaraki	?	1	1] Kano <i>et al</i> (1962) ¹⁷⁾
2	1	M	Ehime	in feces	1	30	
3	newborn infant	F	Fukuoka	eyelid	1	50	Yoneda <i>et Iwami</i> (1981) ¹⁸⁾
4	70	F	Hyogo	in feces	2	7-8	Ogawa <i>et al</i> (1981) ¹⁹⁾
5	56	F	Nagasaki	intestine	?	?	Nakao <i>et al</i> (1984) ²⁰⁾
6	24	M	Shizuoka	in feces	2	many	Natsume (1986) ²¹⁾
7	50	F	Okayama	right ear	1	7	Hatsushika <i>et al</i> (1988) ¹²⁾
8	6	F	Ibaraki	right ear	2	6	[Chigusa <i>et al</i> (1994) ¹³⁾ Sasaki <i>et al</i> (1994) ¹⁴⁾
9	9	F	Oita	in feces	2	2-3] Yoneda <i>et al</i> (1998) ¹⁵⁾
10	59	M	Kumamoto	perianal	2	many	
11	74	M	Hiroshima	left ear	3	3	Present report

F=female, M=male

longitudinal window of the dorsal cornua was fairly large in appearance. The dental sclerite situated just beneath the labial sclerite was comma-shaped and relatively large. The gross morphology of the cephalopharyngeal sclerite definitely suggested that the present larva belonged to the family Sarcophagidae.

The anterior spiracles located on the 2nd segment were small finger-like structures, each with about 25 branches. The respiratory openings of those

spiracles were arranged in two rows (Fig 3). Two sets of posterior spiracles situated on the terminal segment were each equipped with three pairs of spiracular slits, which were surrounded by an incomplete peritreme without button, as shown in Fig 4. The peritreme of the posterior spiracles was a large and D-shaped structure, measuring about 0.3 mm in diameter. The inner slits in both peritremes inclined in ventrolateral directions, and the ventral portions of the middle and outer slits approached each other. The distance between the peritremes was about half the width of the diameter of a peritreme.

Judging from the morphological features, the present specimens were identified as the 3rd instar larvae of *Parasarcophaga similis* (Meade, 1876). Therefore, the present report deals with the 11th finding of human infestation with *P. similis* larvae found in Japan, as indicated in Table 2.^{12-15,17-21)}

DISCUSSION

For many centuries dipterous larvae have been observed to infest the necrotic tissue of wounds and dead animals, and their cleansing action on necrotic tissue was once used medically to débride wounds.¹⁾ At present, myiasis is commonly defined as a condition of dipterous larvae infestation of the organs and tissues of humans or other vertebrate animals, as mentioned above.

Since 1946, human otomyiasis caused by the dipterous larvae of seven species has been reported in Japan, namely by *Boettcherisca peregrina* (Robineau-Desvoidy), *Musca domestica* Linnaeus, *Phaenicia sericata* Meigen, *Parasarcophaga similis* (Meade), *Phaenicia cuprina* (Wiedemann), *Parasarcophaga harpax* (Pandelle) and *Drosophila melanogaster* Meigen in the order of their frequency of appearance (Table 1). The dipterous larvae examined in the present study are among the above-mentioned species.

Dipterous flies develop into adults by complete metamorphosis by passing through three developmental stages; namely, egg, larva (maggot) and pupa. In general, the fully grown adult females of most fly species usually lay their eggs in the habitat, on the hair or body, or in the wounds and diseased tissues of a host. The adult females of some species of the family Muscidae and Sarcophagidae, on the other hand, directly deposit their 1st or 2nd instar larvae. It is well known that sarcophagid larvae usually inhabit night-soil spots, animal carcasses and dumping grounds.

In human cases, infesting dipterous larvae are often found in open wounds, the ear, nose, mouth or accessory sinuses, where they feed on accumulated epidermal debris of the host. This type of infestation is most likely to occur in individuals with an eczematous eruption or poor personal hygiene.¹⁾ Subsequently, these infesting larvae immediately change their form into pupa passing through three stages from 1st to 3rd instars and undergoing two moltings. In this situation, they may provoke myiasis. The average duration of each larval stage is considered to be one to several days, with the durations of the 1st and 2nd instars being only one day each. In sarcophagid flies, an adult female deposits 40 to 80 larvae at a time. The larval stage may be completed as few as four days and the pupal

stage requires eight to ten days. The adult flies normally live about a month under moderately warm summer temperatures.²²⁾

Human myiasis can be divided clinically into two major categories based on the part of the host affected, namely the body cavity, and accidental myiasis except for the cutaneous myiasis caused by the *Dermatobia hominis* maggot.²³⁾ Body cavity myiasis is limited to the nasopharyngeal (auricular, lung and ophthalmic) region, while accidental myiasis occurs in the intestinal (enteric and rectal) and urogenital regions. Most of the cases of human myiasis reported in Japan have been ones of accidental myiasis.

In the present case, it is highly probable that an adult female of *P. similis* dropped the 1st instar larvae on the skin surface around the patient's left ear, and then only three larvae got into the auditory canal. However, it is conceivable that the present patient was unable to brush or pick off the fly larvae on his skin with his hand, because of the gross decline in the motor function of his extremities as described above.

Brown and Neva (1983)²⁴⁾ reported that certain structures of the mature 3rd instar larva are useful for identifying genera and species: (1) shape and ornamentation, (2) structure of the anterior end, the cephalopharyngeal sclerite, (3) the small fan-like, branched anterior spiracles on the 2nd segment, and (4) most important of all, the posterior spiracles on the last abdominal segment. The morphological features of the present specimen closely resembled those of the 3rd instar larva of *P. similis*, described by Ishijima (1967)²⁵⁾ as having the anterior process of the dorsal cornua sharply pointed forward, the hook part of the labial sclerite long and gently pointed downward, a dental sclerite and window of the dorsal cornua of fairly large size, anterior spiracles each with about 25 branches in two rows, a peritreme of the posterior spiracle incompletely encircled and without button, with the distance between both peritremes being narrow.

The first case of human otomyiasis in Japan was reported by Ozawa (1903)²⁶⁾ in Shizuoka Prefecture. Since then about 80 cases have been recorded. Of these, 50 cases were reported before 1945 as summarized by Kano (1959)²⁷⁾ and Ohkawa (1979),⁹⁾ and 31 cases have been found between 1946 and the present-day. These latter cases are summarized in Table 1. As previously mentioned, seven species of dipterous larvae have been recorded as causative agents of human otomyiasis in Japan (Table 1).

As shown in Table 1, the numbers of larvae removed from the 31 patients ranged from 1 to 30, and 2nd instar larvae predominated in the majority of cases except for 20 pieces of incomplete data on the infesting larvae. Although the vast majority of the 31 patients were distributed widely throughout the country, most of them lived in the western Kanto District. The prefectural distribution of these 31 patients was: 16 in Mie, 5 in Tokyo, 2 each in Tochigi and Fukuoka, and one each in Fukui, Okayama, Ibaraki, and Oita. The victims of otomyiasis ranged in age from newborn to 81 years old, and the highest incidence of infestation was found in children under 10 years old. Six of these cases were of newborn infants. Of these 31 victims, five were in age groups above 70 years old including the present case. Regarding the sex distribution, there were about twice as many females as males. Brown and Neva (1983)²⁴⁾ reported that human infestation with sarcophagid larvae is largely confined to infants and small

children, particularly those with nasal discharges, who sleep unscreened, out of doors. As indicated in Table 1, the age distribution of the victims in whom otomyiasis was induced after 1946 is essentially in agreement with the above description by Brown and Neva.

Only 10 cases of human infestation with *P. similis* larvae have previously been reported in Japan (Table 2). In examining Table 2, it can be seen that the ages of the patients ranged from newborn to 77, and there were slightly more females than males. The number of *P. similis* larvae removed from the 10 patients ranged from 1 to 50, and the developmental stages of all the removed larvae were 1st or 2nd instars. Therefore, the infestation with a 3rd instar larva of *P. similis* described in this paper appears to be the first such case. In the past 10 victims, the infestation sites of *P. similis* larvae have been mostly restricted to the digestive system (in feces and the intestine), aside from the eyelid,¹⁸⁾ ear canal¹²⁻¹⁴⁾ and perianal¹⁵⁾ regions (Table 2). Hence, the present case is considered to be the 3rd case of human otomyiasis caused by the *P. similis* larva in Japan.

Human myiasis is in no way contagious from patient to patient under normal circumstances, because the larvae are not capable of reproduction. Transmission of myiasis occurs only via an adult female fly. In the past cases of human otomyiasis indicated in Table 1, however, infesting larvae were found from the middle ear chamber²⁾ and the tympanic cavity^{5,6)} which might have been invaded through a ruptured tympanic membrane. Markell *et al* (1992)²⁸⁾ noted that the most dangerous form of human myiasis is aural myiasis, in which the patient may complain of crawling sensations and buzzing noises, and a foul-smelling mucopurulent discharge may be present. Moreover, if located in the middle ear, the infesting larvae may find their way into the brain, and death is not uncommon.

Although there have as yet been no reliable reports concerning significant disease caused by human otomyiasis in Japan, the authors would like to stress that particular attention should constantly be paid to the prevention of adult fly invasion of houses, especially those with newborn infants or massively physically handicapped persons.

ACKNOWLEDGMENTS

The authors wish to thank Dr. Kieko Iwamoto in Hiroshima City for providing us with materials and also to Misses Kumiko Matoba and Noriko Furukawa of Kawasaki Medical School for their technical assistance.

REFERENCES

- 1) Wilson BB, Weary PE: Maggots (myiasis). *In* Principles and Practice of Infectious Diseases, 3rd ed, eds by Mandell GL, Douglas PG and Bennett JE. New York, Churchill Livingstone. 1990, pp 2166-2167
- 2) Kusaka Y: A case of biotic foreign bodies found in external ear canal, middle ear cavity and mastoid. *Tokyo Jikeikai Med J* **67**: 34-35, 1952 (in Japanese)
- 3) Ijima Y: Two cases of foreign body in external aural canal. *Jap J Otol* **56**: 390, 1953 (in Japanese)
- 4) Fujiwara T: Two cases of external aural foreign body. *Jap J Otol* **57**: 841, 1954 (in Japanese)
- 5) Yoshii M, Ohkawa T: A case of otomyiasis caused by *Phaenicia sericata*. *Jap J*

- Otol **60** : 994, 1957 (in Japanese)
- 6) Kaneko K, Amano K, Kubota K, Hosokawa A : A new human otomyiasis caused by the larvae of *Parasarcophaga harpax*. Jap J Sanit Zool **19** : 248-252, 1968 (in Japanese with English summary)
 - 7) Kawasima T : The foreign bodies in nose and ear. Pediatrics **12** : 511-513, 1971 (in Japanese)
 - 8) Yagisawa M, Nakamura K, Nagai H : Larva infestation of external aural cavity in a new-born infant. Otolaryngol **47** : 643-645, 1975 (in Japanese with English abstract)
 - 9) Ohkawa T : Biotic foreign bodies in otolaryngology. Pract Otol **72** (Suppl. 2) : 1105-1175, 1979 (in Japanese with English summary)
 - 10) Koga K, Kawashiro N, Araki A, Nara T : A case of newborn infant otomyiasis caused by *Boettcherisca peregrina*. Clin Otol Jpn **12** : 306-307, 1985 (in Japanese)
 - 11) Ohyama : Cited from "A case of intestinal myiasis" by Hikita *et al.* Gunma-Shoni-Kaiho **106** : 7-8, 1986 (in Japanese)
 - 12) Hatsushika R, Hyo Y, Okino T : A cases study of otomyiasis caused by *Parasarcophaga similis* (Meade, 1876) (Diptera : Sarcophagidae). Kawasaki Med J **14** : 83-89, 1988
 - 13) Chigusa Y, Tanaka K, Yokoi H, Matsuda H, Sasaki Y, Ikadatsu Y, Baba K : Two cases of otomyiasis caused by *Sarcophaga peregrina* and *S. similis* (Diptera : Sarcophagidae). Jpn J Sanit Zool **45** : 153-157, 1994
 - 14) Sasaki Y, Arakawa K, Hayashi S, Mori A, Baba K, Ikadatsu Y : Two cases of otomyiasis. Pract Otol (Suppl. **70**) : 94-99, 1994 (in Japanese with English summary)
 - 15) Yoneda Y, Shinonaga S, Kumashiro H, Fukuma T : Eleven cases of accidental human myiasis since 1990. Med Entomol Zool **49** : 51-56, 1998 (in Japanese with English summary)
 - 16) Chigusa Y, Shinonaga S, Matsumoto J, Kirinoki M, Otake H, Fukami S, Sasaki K, Baba K, Matsuda H : Aural myiasis due to *Lucilia sericata* (Diptera : Calliphoridae) in a patient suffering from diabetes, hypochondriasis and depression. Med Entomol Zool **50** : 295-297, 1999
 - 17) Kano R, Kaneko K, Kawashima K, So N : On some cases of myiasis. Jpn J Sanit Zool **13** : 96-97, 1962 (in Japanese)
 - 18) Yoneda Y, Iwami H : A case of ophthalmomyiasis externa. Jpn J Sanit Zool **32** : 130-132, 1981 (in Japanese with English summary)
 - 19) Ogawa M, Cho T, Nishiyama W, Mori T, Yazaki S : A case of intestinal myiasis. Surgery **43** : 534-536, 1981 (in Japanese)
 - 20) Nakao K, Goto M, Tajima H, Nakada K, Furukawa R, Sato A, Kawahara K, Ishii N, Kusumoto M, Tohisa T, Shoji T, Nagataki S, Oda T : A case of intestinal myiasis. Jap J Gastroenterol **81** : 2879, 1984 (in Japanese)
 - 21) Natsume M : A case of intestinal myiasis in a patient of psychosomatic disease. Iryo **40** (Suppl.) : 72, 1986 (in Japanese)
 - 22) Harwood RF, James MT : Entomology in Human and Animal Health. 7th ed, New York, Macmillan. 1979, pp 265-266
 - 23) Hall MJR, Smith KGV : Diptera causing myiasis in man. In Medical Insects and Archnids, eds by Lane RP and Crosskey RW. London, Chapman & Hall. 1996, pp 429-469
 - 24) Brown HW, Neva FA : Basic Clinical Parasitology. 5th ed, New York, Appleton-Century-Crofts. 1983, pp 279-282
 - 25) Ishijima H : Revision of the third stage larvae of synanthropic flies of Japan (Diptera : Anthomyiidae, Muscidae, Calliphoridae and Sarcophagidae). Jap J Sanit Zool **18** : 47-100, 1967
 - 26) Ozawa A : Meningitis-like symptom caused by otomyiasis. Chugai-Iji-Shinpo **531** : 315-318, 1903 (in Japanese)
 - 27) Kano R : Myiasis. Hoken-no-Kagaku **1** : 378-380, 1959 (in Japanese)
 - 28) Markell EK, Voge M, John DT : Medical Parasitology. 7th ed, Philadelphia, WB Saunders. 1992, pp 353-358