



Original article

In-stent neointimal characteristics and late neointimal response after drug-eluting stent implantation: A preliminary observation



Kenzo Fukuhara (MD)*, Hiroyuki Okura (MD, FJCC), Teruyoshi Kume (MD, FJCC), Ryotaro Yamada (MD), Yoji Neishi (MD), Shiro Uemura (MD, FJCC)

Division of Cardiology, Kawasaki Medical School, Kurashiki, Japan

ARTICLE INFO

Article history:

Received 10 December 2014

Received in revised form 9 June 2015

Accepted 1 July 2015

Available online 11 August 2015

Keywords:

Drug-eluting stent

Optical coherence tomography

Neointima

ABSTRACT

Background: Progressive neointimal proliferation may lead to late restenosis and/or neoatherosclerosis after drug-eluting stent (DES) implantation. Late neointimal response may be different among different tissue characteristics. The aim of this study was to assess impact of in-stent neointimal characteristics on late neointimal response following DES implantation.

Methods: Serial (median 270 days and median 551 days after stent implantation) optical coherence tomography (OCT) examinations were performed in 42 stented lesions from 26 patients. In-stent neointimal tissue was categorized as either homogeneous or heterogeneous neointima based on the OCT appearance at 1st follow-up. Serial changes in neointimal area (NIA) were compared between lesions with homogeneous neointima and those with heterogeneous neointima.

Results: At first follow-up, homogeneous neointima was observed in 22 (52%) and heterogeneous neointima in 20 (48%) lesions, respectively. During follow-up, NIA in lesions with homogeneous neointima decreased significantly ($1.8 \pm 0.93 \text{ mm}^2$ to $1.5 \pm 0.88 \text{ mm}^2$, $p < 0.001$). On the other hand, NIA in lesions with heterogeneous neointima did not change significantly ($2.7 \pm 1.8 \text{ mm}^2$ to $2.8 \pm 1.6 \text{ mm}^2$, $p = 0.658$). Homogeneous neointima was the only predictor of late neointimal regression (late neointimal regression defined as NIA at first follow-up – NIA at second follow-up < 0) by multivariable analysis (odds ratio = 7.591, 95% confidence interval: 1.616–35.67, $p = 0.010$).

Conclusions: OCT characteristics of neointima after DES implantation may be related to late neointimal progression or regression.

© 2015 Japanese College of Cardiology. Published by Elsevier Ltd. All rights reserved.

Introduction

Previous studies have suggested that progressive neointimal proliferation leads to late restenosis after drug-eluting stent (DES) implantation [1,8]. On the other hand, neointimal regression may also occur in some stented lesions [2]. Late neointimal response may be different between different tissue components [3]. Therefore, prediction of neointimal response based on the in-stent neointimal characteristics may be important for risk stratification of the intermediate in-stent restenosis lesions.

Pathological studies have demonstrated that neointima within a stent are composed of various tissue components including collagen, proteoglycan, smooth muscle, fibrin, or thrombus [12,14,15]. Conventional intracoronary imaging modalities, such

as angiography and intravascular ultrasound, have a limited ability to assess the neointimal characteristics because of their lower resolution and penetration. On the other hand, optical coherence tomography (OCT) has better resolution with acceptable penetration to assess in-stent neointimal tissue [3–5]. Although previous studies using OCT have reported that neointimal tissue have several different optical properties, the relationship between different OCT-based neointimal characteristics and late neointimal response have not been elucidated. Therefore, the aim of this study was to assess the relationship between OCT characteristics of neointima and late neointimal response (progression or regression) following DES implantation.

Methods

Study population

Patients with serial OCT examinations (first follow-up: median 270 days after DES implantation and second follow-up: median

* Corresponding author at: Division of Cardiology, Kawasaki Medical School, Kurashiki 701-0192, Japan. Tel.: +81 86 462 1111; fax: +81 86 462 1199.

E-mail address: kenzofukuhara@yahoo.co.jp (K. Fukuhara).

551 days after DES implantation) were included in this study (42 stented lesions from 26 patients). Patients with in-stent restenosis who required revascularization at first follow-up were excluded. Implantation of stent was performed using current conventional techniques. All patients received dual antiplatelet therapy for at least 1 year after stent implantation. The study protocol was approved by the ethics committee of Kawasaki Medical School, and written informed consent was obtained from each patient. This study was in compliance with the Declaration of Helsinki with regard to investigations in humans.

OCT examination

OCT image acquisition was performed using a commercially available frequency-domain or time-domain OCT system with a motorized pull-back device (C7-XR or M2/M3 OCT Intravascular Imaging System; St. Jude Medical Inc., St. Paul, MN, USA). Qualitative and quantitative OCT assessments of neointima were performed at minimal lumen area (MLA) site at first follow-up. Neointimal area (NIA) was calculated as stent minus lumen area. In addition, maximum thickness of neointima was measured at MLA site. Neointima tissue characteristics were categorized as homogeneous or heterogeneous neointima at first follow-up. Homogeneous neointima was defined as uniform optical properties without focal variation in the backscattering pattern. Heterogeneous neointima was defined as either focally changing optical properties and various backscattering patterns or concentric layers with different optical properties: an adluminal high scattering layer and an abluminal low scattering layer (Fig. 1) [3]. Lumen contour was automatically detected using OCT system software and manually edited if needed. MLA was defined as the minimal lumen area in the segment within the stent. Serial changes in NIA during follow-up period were compared between lesions with homogeneous neointima and those with heterogeneous neointima. In addition, to further determine predictors of late neointimal regression (defined as NIA at first follow-up – NIA at second follow-up < 0), lesions with late neointimal regression were compared with those without late neointimal regression. All OCT images were independently analyzed by two investigators who were unaware of the patient's clinical information. Differences between the observers' analyses were resolved by consensus.

Statistical analysis

Data are presented as mean \pm SD for continuous variables and as frequency (%) for categorical variables. In general, Student's *t*-test was used to compare continuous variables, and the χ^2 test or Fisher exact test was used to compare categorical variables. The predictors of late neointimal regression were investigated with stepwise regression analysis. The Kruskal–Wallis test was used to compare baseline patient characteristics among the three groups of patients: with late neointimal regression, without late neointimal regression, and both with and without late neointimal regression. Statistical analysis was performed with the SPSS (version 22.0 for Windows, SPSS Inc, Chicago, IL, USA), and $p < 0.05$ was considered to be statistically significant.

Results

Clinical characteristics

Baseline clinical characteristics are shown in Table 1. Serial OCT imaging was performed in 42 stented lesions [sirolimus-eluting stents ($n = 8$), paclitaxel-eluting stents ($n = 16$), zotarolimus-eluting stents ($n = 4$), everolimus-eluting stents ($n = 11$), and biolimus-eluting stents ($n = 3$)].

OCT comparison between lesions with homogeneous neointima and heterogeneous neointima

Quantitative assessments by OCT are shown in Fig. 2a. There were no differences in quantitative parameters, such as stent area, lumen area, and NIA between first and second follow-up. Serial changes of neointimal characteristics from first follow-up to second follow-up are shown in Fig. 2b. At first follow-up, homogeneous neointima was observed in 22 (52%) and heterogeneous neointima in 20 (48%) lesions, respectively. During follow-up, 4 lesions with heterogeneous neointima changed to homogeneous neointima. In contrast, no lesions with homogeneous neointima changed to heterogeneous neointima. During follow-up, NIA in lesions with homogeneous neointima decreased significantly ($1.8 \pm 0.94 \text{ mm}^2$ to $1.5 \pm 0.88 \text{ mm}^2$, $p < 0.001$). On the other hand, NIA in lesions with heterogeneous neointima did not change significantly ($2.7 \pm 1.8 \text{ mm}^2$ to $2.8 \pm 1.6 \text{ mm}^2$, $p = 0.658$) (Fig. 3a). Delta NIA from first follow-up to second follow-up was significantly different between lesions with homogeneous neointima

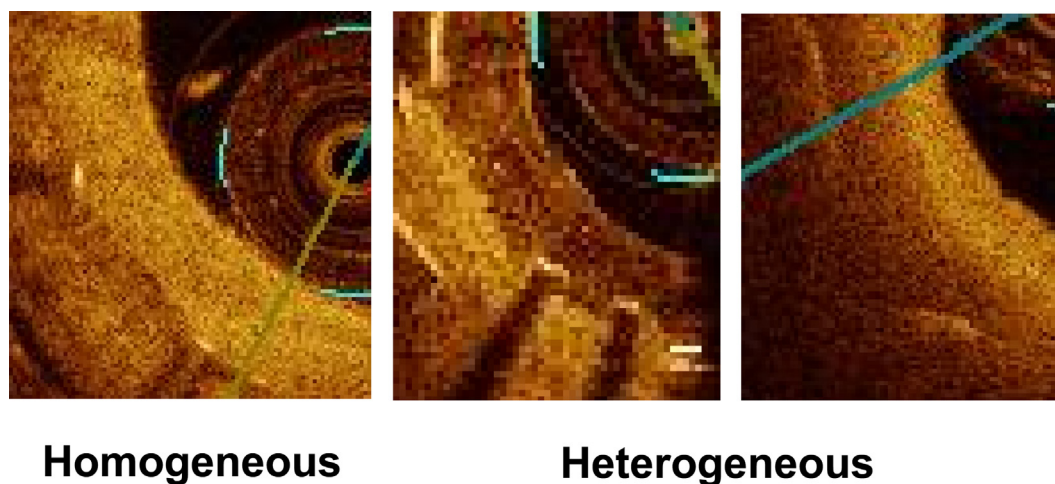


Fig. 1. Optical coherence tomographic (OCT) classification of neointima. OCT characteristic of neointima was categorized as homogeneous, or heterogeneous pattern. Homogeneous pattern is uniform optical properties without focal variations in backscattering pattern. Heterogeneous pattern is focally changing optical properties with various backscattering patterns.

Table 1
Clinical characteristics.

	n = 26
Gender (M/F)	21/5
Age (years)	68 ± 12
SAP/UAP	23/3
DM, n (%)	18 (69)
HL, n (%)	22 (85)
HT, n (%)	20 (77)
Smoking, n (%)	7 (27)
FH, n (%)	4 (15)
MI, n (%)	7 (27)
CABG, n (%)	3 (12)
Hemodialysis, n (%)	2 (8)
Medication	
ACEI/ARB, n (%)	7 (28)
Statin, n (%)	15 (58)
Anti-diabetics, n (%)	13 (50)
β-blockers, n (%)	4 (15)
Ca-channel blockers, n (%)	7 (27)
Aspirin, n (%)	26 (100)
Thienopyridines, n (%)	26 (100)

SAP, stable angina pectoris; UAP, unstable angina pectoris; DM, diabetes mellitus; HL, hyperlipidemia; HT, hypertension; FH, family history; MI, myocardial infarction; CABG, coronary artery bypass graft surgery; ACEI, angiotensin-converting enzyme inhibitors; ARB, angiotensin receptor blockers.

and heterogeneous neointima (Fig. 3a). Delta NIA in individual lesions are shown in Fig. 3b.

Comparison between lesion with and without late neointimal regression

Late neointimal regression was observed in 24 of 42 (57%) lesions. Baseline patient characteristics among the three groups of patients, with late neointimal regression, without late neointimal regression, and both with and without late neointimal regression, are shown in Table 2a. Lesion characteristics between lesion with late neointimal regression and without late neointimal regression are shown in Table 2b. Lesion vessel and stent type, and stent length and diameter were not significantly different ($p = 0.77$, $p = 0.15$, $p = 0.33$, and $p = 0.27$, respectively). Maximum thickness of neointima at MLA site was less than 2 mm in all lesions (0.51 ± 0.29 mm). OCT results comparing the two groups are shown in Table 3. Homogeneous neointima was observed in 17 of 24 (71%) in lesion with late neointimal regression and 5 of 18 (28%) in those without late neointimal regression. By univariable and multivariable analysis, homogeneous neointima at first follow-up was the only predictor of late neointimal regression (Table 4). Representative lesions with homogeneous neointima and heterogeneous neointima are shown in Fig. 4.

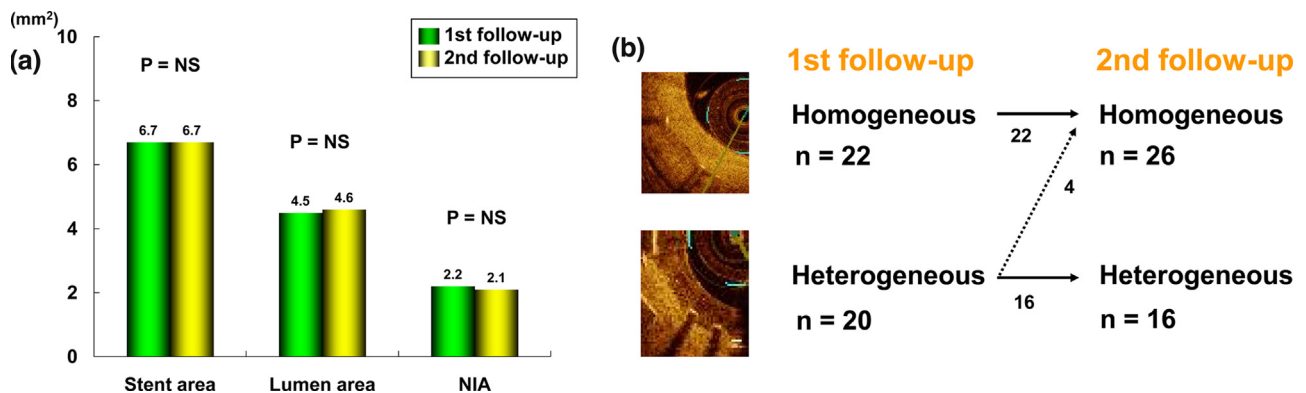


Fig. 2. (a) Optical coherence tomographic quantitative findings. There were no differences in quantitative parameters, such as stent area, lumen area, and neointimal area (NIA), from first follow-up to second follow-up. (b) Serial changes in neointimal characteristics. At first follow-up, homogeneous pattern was observed in 22 (52%) and heterogeneous pattern in 20 (48%) lesions, respectively. From first follow-up to second follow-up, 4 lesions with heterogeneous pattern changed to homogeneous pattern. In contrast, no lesions with homogeneous pattern changed to heterogeneous pattern.

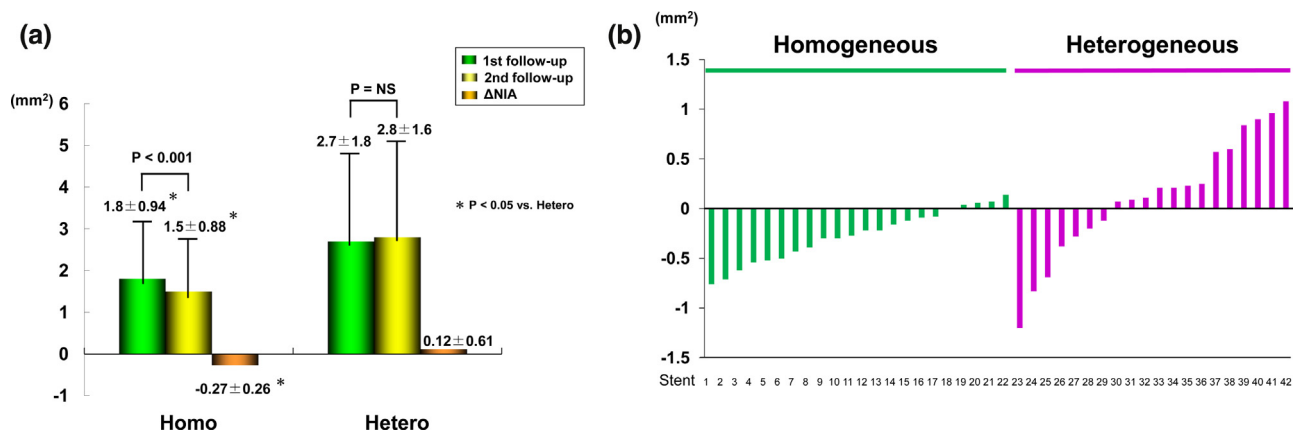


Fig. 3. (a) Serial changes in neointima. During follow-up period, neointimal area (NIA) in lesions with homogeneous pattern decreased significantly, while neointimal area in lesions with heterogeneous pattern did not change significantly. Neointimal area change from first follow-up to second follow-up was significantly different between lesions with homogeneous and heterogeneous patterns at first follow-up. (b) Individual neointimal area changes in lesions with homogeneous and heterogeneous patterns. Late neointimal regression was observed in 17 of 22 lesions with homogeneous pattern and in 7 of 20 lesions with heterogeneous pattern.

Table 2a

Patient characteristics including medication at first follow-up among the three groups of lesions, with LNR, lesions without LNR, and both with and without LNR.

	LNR (+) (n = 10)	LNR (–) (n = 9)	Both with and without LNR (n = 7)	p-value
Male, n (%)	7 (70)	8 (89)	6 (86)	0.54
Age (years)	72 ± 11	70 ± 8	61 ± 14	0.17
DM, n (%)	8 (80)	6 (67)	4 (57)	0.59
HL, n (%)	8 (80)	8 (89)	6 (86)	0.86
HT, n (%)	9 (90)	6 (67)	5 (71)	0.45
Smoking, n (%)	2 (20)	2 (22)	2 (29)	0.92
FH, n (%)	2 (20)	1 (11)	1 (14)	0.86
ACS, n (%)	2 (20)	1 (11)	0 (0)	0.45
Hemodialysis, n (%)	1 (10)	0 (0)	1 (14)	0.53
Medication				
ACEI/ARB, n (%)	1 (10)	5 (56)	1 (14)	0.06
Statin, n (%)	7 (70)	4 (44)	4 (57)	0.53
Insulin, n (%)	3 (30)	0 (0)	2 (29)	0.19
Pioglitazone, n (%)	2 (20)	1 (11)	0 (0)	0.45
β-blockers, n (%)	2 (20)	1 (11)	1 (14)	0.86

LNR, late neointimal regression; DM, diabetes mellitus; HL, hyperlipidemia; HT, hypertension; FH, family history; ACS, acute coronary syndrome; ACEI, angiotensin-converting enzyme inhibitors; ARB, angiotensin receptor blockers.

Table 2b

Characteristics of lesions with late neointimal regression and without late neointimal regression.

	Late neointimal regression (+) (n = 24)	Late neointimal regression (–) (n = 18)	p-value
Lesion vessel			
LAD/LCX/RCA	12/5/7	11/3/4	0.77
Stent type			
1st generation DES/2nd generation DES	16/8	8/10	0.15
Stent length	2.96 ± 0.39	2.85 ± 0.32	0.33
Stent diameter	19 ± 5.9	21 ± 6.4	0.27

LAD, left anterior descending artery; LCX, left circumflex artery; RCA, right coronary artery; DES, drug-eluting stent.

Table 3

Optical coherence tomographic quantitative and qualitative assessments between lesions with late neointimal regression and without late neointimal regression.

	Late neointimal regression (+) (n = 24)	Late neointimal regression (–) (n = 18)	p-value
Quantitative assessments			
1st follow-up			
Lumen area (mm ²)	4.8 ± 2.1	4.1 ± 1.9	0.25
Stent area (mm ²)	7.1 ± 2.5	6.3 ± 1.6	0.29
NIA (mm ²)	2.2 ± 1.5	2.2 ± 1.5	0.96
2nd follow-up			
Lumen area (mm ²)	5.2 ± 2.1	3.8 ± 1.8	0.03
Stent area (mm ²)	7.0 ± 2.4	6.3 ± 1.4	0.32
NIA (mm ²)	1.8 ± 1.3	2.6 ± 1.5	0.08
ΔNIA	0.41 ± 0.28	0.36 ± 0.36	<0.01
Qualitative assessments			
Homogeneous, n (%)	17 (71)	5 (28)	<0.01
NIA, neointimal area.			

Discussion

The main findings of this study are the following: (1) from first follow-up to second follow-up, NIA in lesions with homogeneous neointima decreased significantly while NIA in lesions with heterogeneous neointima did not change significantly; (2) late neointimal regression was observed in 24 of 42 (57%) lesions and

Table 4

Independent risk factors for the presence of late neointimal regression on multivariate logistic regression analysis.

	OR	95% CI	p-value
Homogeneous pattern	7.591	1.615–35.67	0.010
ACEI/ARB	1.402	0.186–10.54	0.743
Insulin	2.080	0.384–11.28	0.396

ACEI, angiotensin-converting enzyme inhibitors; ARB, angiotensin receptor blockers.

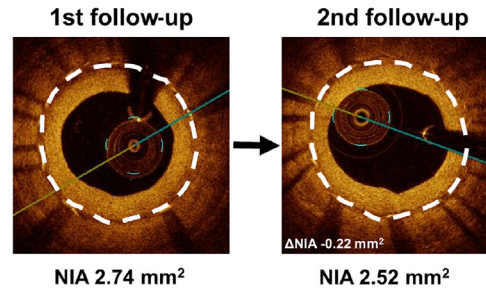
homogeneous neointima was the only predictor of late neointimal regression by multivariable analysis.

Pathological studies have demonstrated that neointima within a stent is composed of various tissue components including collagen, proteoglycan, smooth muscle, fibrin, or thrombus [12,14,15]. Gonzalo et al. reported that there were various variety of neointimal characteristics after stent implantation [3]. In the present study, homogeneous neointima at first follow-up was the only predictor of late neointimal regression from first follow-up to second follow-up. These data suggested that OCT characteristics of neointima may be related to late neointimal response after DES implantation. If late neointimal regression after DES implantation could be predicted at first follow-up, repeated intervention for mild to intermediate in-stent lesion might be safely deferred.

It has been reported that neointima having smooth muscle cells with a little collagen and elastin showed homogeneous pattern on OCT [6]. On the other hand, neointima having fibrin accumulation along with smooth muscle cells showed heterogeneous pattern on OCT [9]. Neointima healing process was due to fibrin deposition substitution for smooth muscle cells after stent implantation [10]. This healing process, especially after bare-metal stent implantation, was completed 28 days after stent implantation, and late neointimal regression between 6 months and 3 years is well recognized after bare metal stent implantation [10,11]. In contrast, DES delays neointimal healing process after stent implantation [12]. In the present study, 4 lesions with heterogeneous neointima on OCT changed to homogeneous neointima from first follow-up to second follow-up. This might be due to delayed healing after DES implantation. By contrast, presence of homogeneous neointima at first follow-up, as is usually seen after bare-metal stent implantation, may suggest that neointimal healing process is not delayed and thus may be completed at the time of the first follow-up. Considering that homogeneous neointima after bare-metal stent usually regress between 6 months and 3 years, similar change might be expected for DES with homogeneous neointima [7].

Recently, Kang et al. reported that OCT could detect atherogenic changes within neointima (so-called neoatherosclerosis) and significant relation between the presence of neoatherosclerosis and late DES failure [13]. Pathological study demonstrated that neoatherosclerosis was a frequent finding after DES implantation (median stent duration: 420 days) [14]. Therefore, it is possible that some of the in-stent neointima with homogeneous pattern become lipid laden neointima or neoatherosclerosis over time. Previous OCT studies defined in-stent neoatherosclerosis as signal-poor region with marked signal attenuation [13]. This could be categorized as heterogeneous neointima by our present definition. In our study population, however, not a single DES with homogeneous neointima has been documented to become heterogeneous neointima during follow-up. This may be explained by the small sample size and relatively shorter follow-up period. The underlying mechanisms responsible for the neoatherosclerosis might be multifactorial. Therefore, further large number of serial OCT imaging may be needed to elucidate the incidence and

Homogeneous pattern at 1st follow-up and neointimal regression



Heterogeneous pattern at 1st follow-up and neointimal progression

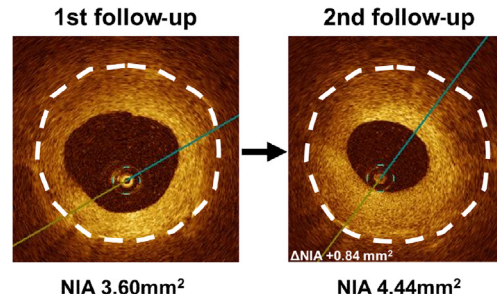


Fig. 4. Representative lesions showing homogeneous and heterogeneous patterns at first follow-up. Neointimal area (NIA) in lesion with homogeneous pattern at first follow-up decreased by 0.22 mm² during follow-up period. Neointimal area in lesion with heterogeneous pattern at first follow-up increased by 0.84 mm² during follow-up period.

predictors of neoatherosclerosis in DES-treated lesions with homogeneous neointima by OCT.

Limitations

This study has several limitations. First, this study was a retrospective, observational study in a relatively small number of lesions. Second, the number of study lesions was not large enough to perform separate analyses according to the type of implanted stent. Neointimal reaction after stent implantation was different even among different types of drug-eluting stent. This difference might affect the neointimal reaction during follow-up period.

Conclusions

OCT characteristics of neointima after DES implantation may be related to late neointimal progression or regression. Further research in a large number of patients to examine the neointimal characteristics on cardiovascular outcomes is needed.

Funding

This research received no grant from any funding agency in the public, commercial, or not-for-profit sectors.

Disclosure

The authors declare that there is no conflict of interest.

References

- [1] Kuriyama N, Kobayashi Y, Nakama T, Mine D, Nishihira K, Shimomura M, Nomura K, Ashikaga K, Matsuyama A, Shibata Y. Late restenosis following sirolimus-eluting stent implantation. *JACC Cardiovasc Interv* 2011;4:123–8.
- [2] Park GM, Park DW, Kim YG, Cho SW, Sun BJ, Hwang KW, Kim YR, Ahn JM, Song HG, Kim WJ, Lee JY, Kang SJ, Lee SW, Kim YH, Lee CW, et al. Long-term luminal change after drug-eluting stent implantation: serial angiographic follow-up study of the ZEST randomized trial. *Catheter Cardiovasc Interv* 2013;81:274–82.
- [3] Gonzalo N, Serruys PW, Okamura T, van Beusekom HM, Garcia-Garcia HM, van Soest G, van der Giessen W, Regar E. Optical coherence tomography patterns of stent restenosis. *Am Heart J* 2009;158:284–93.
- [4] Hou J, Jia H, Liu H, Han Z, Yang S, Xu C, Schmitt J, Zhang S, Yu B, Jang IK. Neointimal tissue characteristics following sirolimus-eluting stent implantation: OCT quantitative tissue property analysis. *Int J Cardiovasc Imaging* 2012;28:1879–86.
- [5] Nagoshi R, Shinke T, Otake H, Shite J, Matsumoto D, Kawamori H, Nakagawa M, Kozuki A, Hariki H, Inoue T, Ohsue T, Taniguchi Y, Iwasaki M, Nishio R, Hiranuma N, et al. Qualitative and quantitative assessment of stent restenosis by optical coherence tomography: comparison between drug-eluting and bare-metal stents. *Circ J* 2013;77:652–60.
- [6] Kume T, Akasaka T, Kawamoto T, Watanabe N, Toyota E, Sukmawan R, Sadahira Y, Yoshida K. Visualization of neointima formation by optical coherence tomography. *Int Heart J* 2005;46:1133–6.
- [7] Goto I, Itoh T, Kimura T, Fusazaki T, Matsui H, Sugawara S, Komuro K, Nakamura M. Morphological and quantitative analysis of vascular wall and neointimal hyperplasia after coronary stenting: comparison of bare-metal and sirolimus-eluting stents using optical coherence tomography. *Circ J* 2011;75: 1633–40.
- [8] Shibuya M, Fujii K, Fukunaga M, Imanaka T, Miki K, Tamaru H, Ohyanagi M, Masuyama T. Natural history of low-intensity neointimal tissue after an everolimus-eluting stent implantation: a serial observation with optical coherence tomography. *Heart Vessel* 2015;30:136–9.
- [9] Nakano M, Vorpahl M, Otsuka F, Taniwaki M, Yazdani SK, Finn AV, Ladich ER, Kolodgie FD, Virmani R. Ex vivo assessment of vascular response to coronary stents by optical frequency domain imaging. *JACC Cardiovasc Imaging* 2012;5:71–82.
- [10] Farb A, Sangiorgi G, Carter AJ, Walley VM, Edwards WD, Schwartz RS, Virmani R. Pathology of acute and chronic coronary stenting in humans. *Circulation* 1999;99:44–52.
- [11] Kimura T, Abe K, Shizuta S, Odashiro K, Yoshida Y, Sakai K, Kaitani K, Inoue K, Nakagawa Y, Yokoi H, Iwabuchi M, Hamasaki N, Nosaka H, Nobuyoshi M. Long-term clinical and angiographic follow-up after coronary stent placement in native coronary arteries. *Circulation* 2002;105:2986–91.
- [12] Joner M, Finn AV, Farb A, Mont EK, Kolodgie FD, Ladich E, Kutys R, Skorija K, Gold HK, Virmani R. Pathology of drug-eluting stents in humans: delayed healing and late thrombotic risk. *J Am Coll Cardiol* 2006;48:193–202.
- [13] Kang SJ, Mintz GS, Akasaka T, Park DW, Lee JY, Kim WJ, Lee SW, Kim YH, Whan Lee C, Park SW, Park SJ. Optical coherence tomographic analysis of in-stent neoatherosclerosis after drug-eluting stent implantation. *Circulation* 2011;123:2954–63.
- [14] Nakazawa G, Otsuka F, Nakano M, Vorpahl M, Yazdani SK, Ladich E, Kolodgie FD, Finn AV, Virmani R. The pathology of neoatherosclerosis in human coronary implants bare-metal and drug-eluting stents. *J Am Coll Cardiol* 2011;57: 1314–22.
- [15] Matsumoto D, Shinke T, Nakamura T, Shite J, Li J, Hou D, Chronos N. Optical coherence tomography and histopathological assessment of delayed arterial healing after drug-eluting stent implant in a pig coronary model. *Int J Cardiol* 2013;170:152–9.